



REVIEW ARTICLE

Retrograde tracheal intubation

S. S. Dhara

Visiting Medical Officer, Department of Anaesthesia, Royal Hobart Hospital, Hobart, Tasmania, Australia

Summary

Successful management of difficult tracheal intubation by retrograde intubation has been reported for almost 50 years and can be used whether or not it is anticipated. There are numerous reports of variations to the basic technique to enhance reproducibility of this guided blind procedure. A review and analysis of the equipment and techniques provides a better understanding of this effective technique.

Correspondence to: Dr Sasanka Sekhar Dhara

E-mail: sasanksd@yahoo.com

Accepted: 15 June 2009

Tracheal intubation over a guide introduced in a retrograde manner from below the vocal cords and brought out through the mouth or nose, is popularly known as retrograde intubation. Guided blind intubation [1] or trans-laryngeal intubation [2, 3] is perhaps a better description.

The main advantage of this technique over common anterograde techniques of tracheal intubation is that the laryngeal inlet does not have to be identified or negotiated. Instead, the tracheal tube is railroaded directly into the larynx over a retrograde guide previously placed percutaneously inside the larynx. The function of this guide is to keep the tip of the tracheal tube in the midline inside the mouth and the pharynx facilitating its progress across the upper airway into the larynx.

In the past 50 years, there have been numerous publications of use of retrograde intubation ranging from reports of a single or few cases to series [1–20] of cases. A variety of equipment and variations to the basic technique are described for planned as well as emergency management (Table 1) of difficult intubation in adults and children [1, 5, 13].

In the first report of retrograde intubation, an oro-tracheal tube was railroaded over a 16FG catheter with a curved wire stylet inside, placed through the pre-existing tracheostomy into the mouth. Major cancer surgery around the neck in these patients was facilitated by absence of the tracheostomy wound and the tube in the surgical field, providing maximal surgical exposure [4]. A similar technique has been reported with the use of a tracheal tube introducer [21, 22] and fiberoptic scope [23, 24] as a guide.

Commonly, a thin guide such as an epidural catheter or a vascular guide wire is introduced from subglottic area and is used for guiding a tracheal tube into the larynx. Waters reported this technique for successful nasotracheal intubations in older children with severely restricted mouth opening caused by cancrum oris [1].

Some of the steps used during retrograde intubation are familiar to anaesthetists and include applying local anaesthetic to the upper airway, sedation, needle cricothyrotomy and guided blind tracheal intubation over an introducer. Needle cricothyrotomy in cephalad direction, placement of a guide along a desired route and guiding the tracheal tube over it may be less familiar but can be easily learnt [37, 38].

Steps of retrograde intubation

Subglottic access to the airway

The site of puncture

Puncture of the cricothyroid or the cricotracheal membrane is used for access into the larynx. Injury to the vocal cords and the surrounding tissues is possible from the puncture at the cricothyroid membrane as the distance in between is small [39–41]. In a study on fresh cadavers, the incidence of damage to the vocal cords was 8% from needle cricothyrotomy [40]. The cricothyroid artery, a branch of the superior thyroid artery and occasionally another branch from the same artery are present on the cricothyroid membrane [42]. Inserting the guide through the cricotracheal membrane has the main advantages of avoiding injury to the artery or the vocal cords [39, 40].

Table 1 Range of clinical indications for retrograde intubation.

<p>Anticipated difficult intubation</p> <p>To bypass existing tracheostomy for better surgical exposure [4, 21–24]</p> <p>Trismus [1, 5, 25]</p> <p>Small mouth with protruding upper teeth [81]</p> <p>Congenital anomalies – resulting in micrognathia, short neck, large tongue, limited neck movement and mouth opening and cervical spine abnormalities [13, 23, 26–28]</p> <p>Trauma – maxillofacial, cervical spine [10, 11, 16, 29]</p> <p>Tumour – tongue, mandible, floor of the mouth, pharynx and larynx [6, 9, 12, 15, 81]</p> <p>Infection – retropharyngeal abscess [30], acute epiglottitis [31]</p> <p>Bone and joint disorders – rheumatoid arthritis, ankylosing spondylitis, unstable cervical spine [16, 32, 33]</p> <p>Obstructive Sleep Apnoea [12]</p> <p>Microstomia [12]</p> <p>Burns [34]</p> <p>Failed intubation</p> <p>With blind nasal, direct laryngoscopic or fiberoptic scope guided technique [5, 8, 11, 18, 19, 24, 28, 35–36, 79–81]</p>

With cricotracheal puncture, pressure caused by a taut guide is exerted on to the solid cricoid ring rather than the softer ligament of the cricothyroid membrane which is prone to being split easily, causing local surgical emphysema and bleeding [39].

Injury to the thyroid gland while using cricotracheal approach may be avoided by inserting the needle at a point where the skin is closest to the cricoid cartilage [40].

Using cricotracheal access has other advantages relating to guiding the tracheal tube and is discussed in subsection ‘Depth of insertion’ in section ‘Tracheal intubation over a guide’.

The area chosen is palpated and the patient is optimally positioned for access before the front of the neck is cleaned and draped.

The needle for laryngeal access

The epidural (Tuohy type) needle is a popular choice as it is familiar, easily available and has a bevel that helps to direct the guide in the intended direction.

A central venous catheterisation kit with long catheter inside the needle had been used as a convenient ‘ready to use’ sterile pack providing needle and a guide [2, 8, 11, 12, 18].

Vascular access catheters (16–20G) are commonly used now [3, 9, 12–14, 16, 20, 43].

Local anaesthetics/sedation/general anaesthesia

In awake patients the skin and the subcutaneous tissue over the site of access to the larynx is infiltrated with 2% lignocaine. Surface analgesia of the mucus membrane of the mouth, pharynx and laryngeal inlet area is achieved with instillation of 4% lignocaine. Cophenylcaine™ spray containing lignocaine HCl 5% and phenylephrine

HCl 0.5% is used inside the nostrils when nasal intubation is planned. A trans-tracheal injection of 2 ml of 4% lignocaine or bilateral superior laryngeal nerve block using 2% lignocaine helps to suppress the reflexes from inside the larynx [39], vocal cords and upper trachea during the procedure.

Retrograde intubation has also been carried out with conscious sedation [2, 6, 7, 14] and general anaesthesia with or without the use of neuromuscular blocking drugs [1, 4, 5, 8, 9, 15].

Needle cricothyrotomy

The guide being directed cephalad, a right-handed operator needs to stand on the right side of the patient facing the subject, to palpate and stabilise the larynx using the left hand while performing the cricothyrotomy with the right.

The luminal space of the larynx is found with free aspiration of air using a saline filled syringe attached to the cricothyrotomy needle which is angled at 90 °C to the skin initially. Due to the soft cartilage structure allowing luminal compression in children and young adults, care must be taken to avoid excessive force and injury to the larynx. A cut on the skin at the point of puncture, application of lateral stabilising pressure and controlled pressure on the puncture needle can help prevent accidental injury to the posterior wall of the larynx and oesophagus.

Once the laryngeal cavity is reached, the needle/catheter is advanced at a 45° angle in cephalad direction. To prevent injury to the vocal cords, the needle inside the cannula could be partially withdrawn into the catheter while it is advanced into the larynx.

Placement of a retrograde guide

The Guide

A variety of materials have been used as a guide (Table 2).

The flexibility and guiding ability of a guide wire is determined by its thickness. Vascular guide wires of diameters of 0.889–0.965 mm used as a guide in adults are

Table 2 Retrograde guides.

<p>Vinyl plastic tubing [1]</p> <p>Epidural catheters [5, 7, 16–18, 40, 52, 65, 66, 73]</p> <p>Long catheters inside needle [2, 8, 11, 18, 35]</p> <p>Pulmonary artery catheter guide wire [44]</p> <p>Straight guidewire [2, 11, 13, 15, 20, 27, 45]</p> <p>Angiography catheter exchange guide wire [12]</p> <p>‘J’ tipped guide wire [14, 46]</p> <p>Ureteral stent [29]</p> <p>Nylon cord, surgical suture material [6, 10, 36]</p> <p>The Minitrach (Non Seldinger kit, Smith Medical International, Watford, UK) dilator [47, 48]</p>

stiffer and more visible than 14–16G epidural catheters. Guide wires also stand prouder from the pharyngeal wall making retrieval easier and provide stronger support for guiding a tracheal tube. The length of the retrograde guide required is the total of distance from the point of laryngeal puncture to the lip or nostril, plus the length of the tracheal tube plus a length at both ends for ease of manipulation. A length of 70 cm is adequate in adult patients [49]. A longer retrograde guide may be needed when an anterograde guide is interposed over it.

A 'J' tipped guide wire passes through the upper airway smoothly and a rotary movement on its axis makes displacement of the tip obvious and making it easy to pick up from the mucosal surface inside the pharynx [46].

Coated guide wires with smoother surface travel through the punctured laryngeal membrane more easily than uncoated ones. Smaller catheters and guide wires are chosen for paediatric use [13, 26, 27].

Long central venous line catheters were preferred in one report dealing with maxillofacial trauma because it allowed air injection creating bubbles that helped in locating the catheter inside the mouth [11].

The route – oral and nasal

When the guide is passed upwards from the larynx, it may come out from the mouth, coil inside the pharynx or sometimes exit from one of the nostrils. When performed as an awake technique the patient may be able to 'spit' the retrograde guide out of the mouth. Alternatively, when there is adequate mouth opening, it may be picked up from the mouth or pharynx with fingers or a pair of forceps.

In patients with limited mouth opening retrieval of the guide can be difficult. Achieving naso-tracheal intubation can also be challenging.

Historically, a metal hook fixed to the end of a length of polyvinyl tubing and placed inside a nasal tube (to avoid turbinate injury) was passed into the pharynx to bring the guide out through the nose [1]. Loss of the hook was reported with this technique and was replaced with all-metal wire hooks [5, 50].

A catheter introduced into the nose, brought out from the mouth to bring the guide out from the mouth to the nose works well. In most reports the end of a nasally placed catheter is either tied or stitched to the upper end of the guide to pull it out from the nose [2, 4, 6, 26, 28]. Threading the guide through the larger lumen of the nasally placed catheter [7] is quicker, easier and reduces the chance of potential trauma to the turbinates caused by pulling a knot of catheters through it.

A loop of guide wire through a small non-cuffed tracheal tube (pharyngeal loop) has been described for picking up the guide from the pharynx. The loop introduced through the nose is opened wide inside the

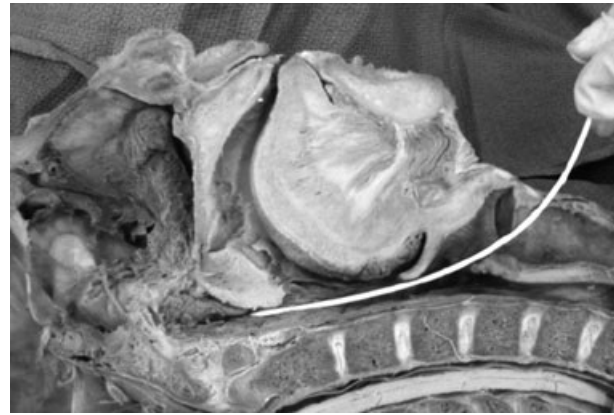


Figure 1 Tip of a long of cricothyrotomy catheter against posterior nasal aperture.

oro-pharynx to place the guide inside it. It is then grabbed by closing the loop and brought out from the nose [51].

Suction through a nasally placed catheter to bring out the epidural catheter (retrograde guide) from the pharynx [52] and fluoroscopy to manipulate the guide have been reported [53].

Insertion of a longer length of cricothyrotomy catheter helps to bring the guide out through the nostril [14]. The tip of the catheter guided by the contour and confines of the posterior pharyngeal wall leads to the posterior nasal aperture (Fig. 1).

Tracheal intubation over a guide

Problems and failures with endotracheal intubation over a bougie, flexible fiberoptic scope or an airway exchange catheter are common and the mechanics are well known [54–56]. Equipment and manoeuvres for successful railroading [57–63] including a flexible tracheal tube, a close fitting introducer inside the tracheal tube and posterior presentation of the bevel of the tracheal tube at the laryngeal inlet are applicable at this stage.

Retrograde intubation may be performed using a retrograde guide only or over an additional anterograde guide. The retrograde guide has also been used to facilitate other techniques of tracheal intubation.

Intubation using a retrograde guide only

Depth of insertion

The guide tip, unlike an introducer for tracheal intubation, is not freely located in the tracheal lumen but is attached to the anterior wall of the larynx and the tracheal tube can only be advanced along it to that point.

The depth of insertion is the distance between the vocal cords and the point of puncture (Fig. 2). When the

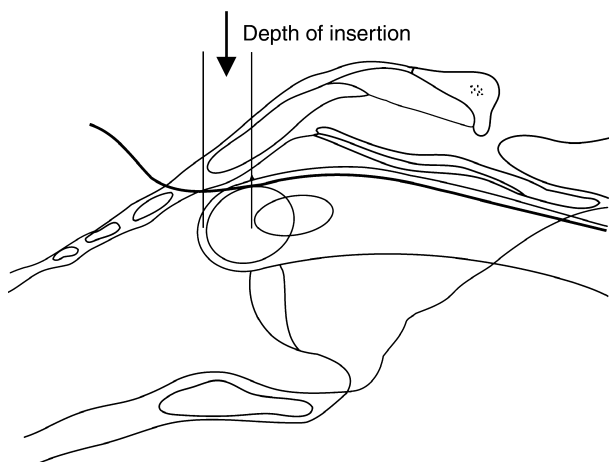


Figure 2 Depth of insertion – distance between the point of puncture on the laryngeal wall and the vocal cords.

cricothyroid membrane is used, the depth of insertion is approximately 9.8 mm [42] in adults and can be less than 5 mm in children [13].

The tip of a stiff tracheal tube has been known to spring out when the grip on the guide is removed [2–4, 25, 35, 64, 65]. This may also result in oesophageal intubation. A longer length of the tracheal tube inside the larynx may reduce the chance of such displacement.

The depth of insertion is greater with the cricotracheal the cricothyroid approach. The guide placed through the cricotracheal space is also more in the centre of the larynx allowing room anteriorly that is useful for easier progress of the tracheal tube [29, 39]. Use of the space between first two tracheal rings has also been reported [18, 39].

Coughing and gagging could contribute towards dislodgement of the tracheal tube from the larynx.

Tension on the retrograde guide

A flexible guide lacks the thickness and stiffness of a conventional tracheal tube introducer (e.g. a bougie) and is not as efficient for guiding. It tends to form a redundant loop inside the pharynx and may get pulled away by the stiff tracheal tube with a tendency to go in a straighter line into the oesophagus. Depending on the consistency of the tracheal tube and the force applied to it, the tip may bend the guidewire between the laryngeal inlet and the oesophagus. A guide, once bent this way may not work and needs to be replaced.

Keeping the guide taut improves its ability as an introducer. The tension required is crucial and has to be gauged carefully. Too much tension on the guide at both ends creates a cheese wire effect sinking the guide more into the tongue, epiglottis, arytenoids or anterior commissure. This impedes the path of the tip of the tracheal tube and can cause trauma with persistent

attempts. The stretch on the guide needs to be relaxed enough to allow further advancement of the tube into the larynx [12, 13].

Prevention of dislodgement of the tracheal tube

(i) Once the tube cannot be advanced any further over the guide and unobstructed breathing through it (in patients breathing spontaneously) is confirmed, it is fair to assume that the tip of the tube is engaged in the laryngeal inlet. At this stage application of axial pressure on the tube stabilises its position inside the larynx. This manoeuvre also helps the tube to be advanced into the trachea as soon as the hold of the guide is removed.

Tracheal tubes made of polyvinyl chloride when compared with armoured and silicon tubes have been shown to exert considerably higher pressure on the point of contact [66]. Application of overzealous pressure has resulted in folding of the tube inside the airway [67].

Accidental dislodgement of the tracheal tube caused by withdrawal of the guide has been addressed by cutting the epidural catheter flush with the skin at the point of puncture. The hold of the guide is thus released to let the tip of the tracheal tube drop from the anterior wall into the larynx [68, 69].

(ii) To harness and guide the tip of the tracheal tube into the lumen of the larynx and to achieve greater depth of insertion, various techniques have been used. An 'inside out' method by threading the guide through the tip of the tracheal tube and bringing it out through the Murphy eye is useful in stabilising and directing it into the larynx [2] (Fig. 3). Insertion of the tracheal tube by an additional centimetre is achieved by using an 'outside in' technique when the guide is threaded through the Murphy eye from outside and brought out through the lumen of the tube [64]. In a cadaver study of retrograde intubation greater success was achieved using combination of passing the guide through the subcricoid space and use of 'outside in' technique [40].

There are reports of stitching and tying or applying a loop of the guide to the tip of the tracheal tube followed by pulling the guide from the neck end to bring the tube from the pharynx into the larynx [6, 10, 17, 18, 28, 33, 70, 71] (Fig. 3).

Retrograde intubation using an anterograde guide over a retrograde guide

To impart added stiffness and to reduce the gap between the tracheal tube and the guide, a hollow anterograde guide may be threaded over the retrograde guide to facilitate advancement of the tube. Guiding a tracheal tube using either a retrograde or an anterograde guide is more likely to be successful when the tube need not

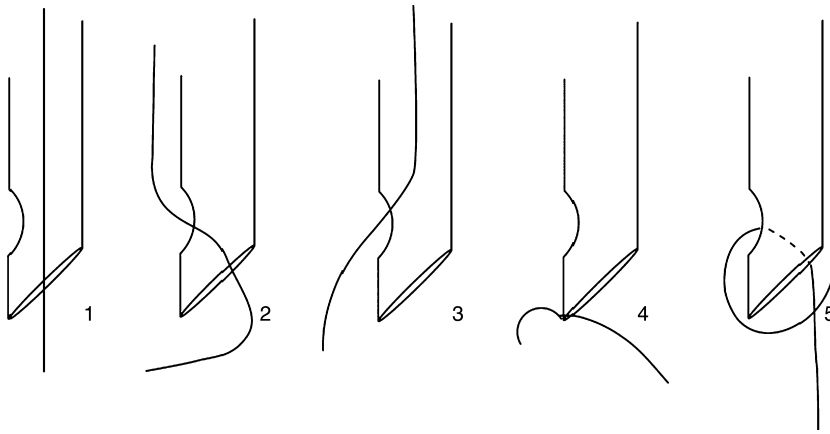


Figure 3 Guide through the end of the tracheal tube and out from the Murphy's eye (2) and through the Murphy's eye into the upper lumen of the tracheal tube (3) lend more stability and depth of insertion than guiding the tube straight (1) over the retrograde guide. The tip of the tube is harnessed either by retrograde guide stitched to it (4) or by a loop of retrograde guide tightened around it (5) and is then pulled down from the pharynx into the larynx.

Table 3 Anterograde guides.

Suction catheters (cooled for added firmness) [66, 67]
Eschmann™ guide modified by severing the end [72]
Guide wire sheath [3]
Multi-lumen catheter [14]
Airway exchange catheter [73]
Custom made guide made by Cook (Cook Critical care, Bloomington, IN, USA)
Flexible fiberoptic endoscope [13, 25, 79–81]

negotiate very acute oro-pharyngeal or pharyngo-laryngeal angle. Tracheal intubation over an anterograde guide is more reliable in difficult circumstances [20, 66, 67, 71, 76], and it would be logical to use it every time. Implements used as an anterograde guide are listed in Table 3.

A tapered tip on the anterograde guide facilitates its smooth passage over the retrograde guide across the airway. The guide wire sheaths from central venous catheterisation kit have varying diameters and do not have tapered ends but have been used successfully as an anterograde guide [3]. An external diameter of 4–5 mm may be most suitable.

Monitoring the progress of the anterograde guide

An anterograde guide may not always follow the course of a retrograde guide all the way into the trachea.

In the Cook retrograde intubation set (Cook Critical care, Bloomington, IN, USA) there are markings on both the guide wire and the custom made anterograde guide. Matching the markings on both confirms correct positioning of the latter inside the airway. Continuous measurement of carbon dioxide through a hollow introducer can be used to distinguish tracheal from oesophageal placement [74].

The puncture cannula over the retrograde guide left inside the pharynx can serve as an indicator as it is pushed

out of the airway by the advancing tip of the anterograde guide [14].

Prevention of dislodgement of the tracheal tube

Dislodgement of the anterograde guide, the guide/tracheal tube assembly or the tracheal tube from a shallow depth of insertion can occur in the similar way as during guiding of the tracheal tube directly over the retrograde guide. The strategies described to prevent this are:

(i) Application of pressure on the tracheal tube. Sustained axial pressure is applied on the guide, the assembly or just the tube as mentioned for guiding the tube over a retrograde guide.

(ii) Pulling the tip of the anterograde guide. The tip of the anterograde guide is stitched onto a more flexible retrograde guide and pulled down into the larynx [9, 75]. Once the position is confirmed, a tube is passed over it.

(iii) Use of an anchor inside the trachea. While the retrograde guide is inside the airway, another guide is positioned deep inside the trachea (anchor) [14, 28, 68, 69, 76, 77]. The anterograde guide and/ or the tracheal tube is advanced over it (Fig. 4) once the hold on the

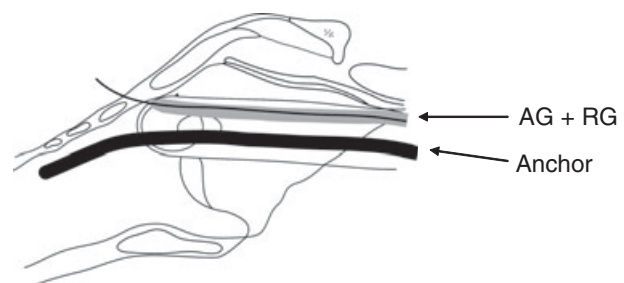


Figure 4 In addition to an anterograde guide (AG) over retrograde guide (RG) an anchoring introducer is passed through the tracheal tube into the trachea.

retrograde guide is released. If the tracheal tube becomes dislodged from the larynx, a length of the anchor inside the trachea would still be available that can be used to guide it back into the larynx and trachea. An anchor offers stability to the tip of the tracheal tube inside the larynx and provides a guide deeper inside the trachea adding extra reliability to the procedure.

This concept was reported with use of a suction catheter as an anterograde guide and a gum elastic bougie as the second guide ('anchor') [68, 69].

The diameters of the anterograde guide and the anchor used should be carefully considered. For example, a tracheal tube with an internal diameter of 10 mm would be needed to accommodate the commonly used 14FG suction catheter and a 15FG bougie. A smaller tracheal tube is normally used during management of a difficult intubation.

In the double guide wire technique [14], an introducer is placed inside the trachea with the help of a second guide wire. It is possible to use a longer length of an anchor ('J' tipped guide wire) inside the trachea without the possibility of causing trauma to the airway. The technique is illustrated with a guide wire sheath (Fig. 5).

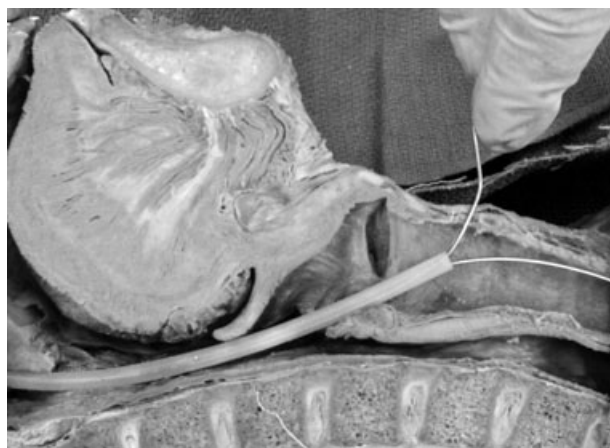


Figure 5 Anchoring with guide wire through a guide wire sheath.

The flexible fiberoptic endoscope has been used as an anchor and an introducer with added advantage of visual confirmation of the position of the tube inside the trachea [33, 76, 77].

In a cadaver study, tracheal intubation was achieved by the use of the same anterograde guide twice. After advancement of the tracheal tube into the larynx over an anterograde guide (a guiding hollow catheter from the Cook Retrograde Intubation Set, Cook, Charenton, France) loaded over a retrograde guide (Fig. 6a), the anterograde guide is withdrawn from the retrograde guide. It is then reinserted through the lumen of the tracheal tube (Fig. 6b) into the trachea, the retrograde guide is removed and the tracheal tube is then advanced over the anchor [78].

This method is claimed to offer significantly improved success compared with the commonly adopted method of applying pressure on the tracheal tube and the anterograde guide during removal of retrograde guide.

Retrograde guide to facilitate other methods of tracheal intubation

The challenges of anterograde flexible fiberoptic endoscope guided intubation are finding and negotiating the larynx to reach the trachea by endoscope manipulation followed by tracheal intubation over the scope. This requires some skill and experience and may be foiled by secretions, blood or abnormal anatomy. The use of the suction channel of the fiberoptic endoscope to guide it over a retrograde guide is dependent on a dry field for vision or operator skill with a fiberoptic scope. The retrograde guide is removed under vision and tracheal intubation is achieved by railroading the tube over the fibrescope [13, 15, 25, 79–81].

Placing a retrograde wire through a laryngeal mask airway [82, 83] for intubation over it has the advantage of having a direct working conduit between the mouth and the laryngeal inlet for easy retrieval of the wire, guiding of the tracheal tube over it and controlled oxygenation and ventilation during the procedure.

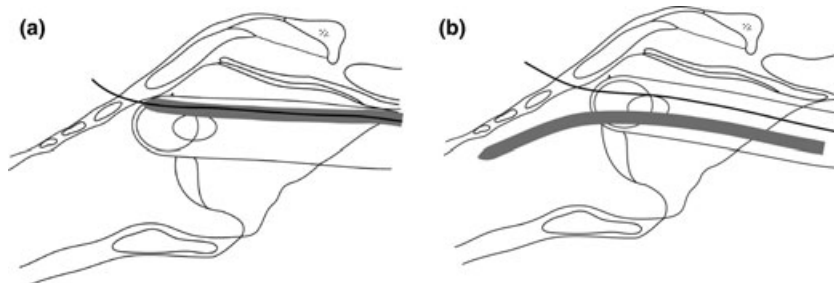


Figure 6 Illustration of single anterograde guide (a) being used as an anchor and an introducer (b).

Table 4 Reported complications of Retrograde Intubation. Refs [5, 8–11, 20, 23, 84–88].

Sore throat and hoarseness
Minor bleeding at site of puncture and inside the trachea
Loss of hook (historical)
Peritracheal haematoma
Mediastinal haematoma
Breath holding
Local surgical emphysema
Folding of tracheal tube inside the airway
Pretracheal abscess
Part of guide wire left in the wound and the vocal cords
Pneumomediastinum
Upper airway obstruction secondary to extension of surgical emphysema

Retrograde intubation using a malleable light wand as an anterograde guide threaded over a guide wire had been used successfully for a series of cases [16]. Correct laryngeal placement of the anterograde guide is confirmed by transillumination of the larynx.

Complications of retrograde intubation

Complications commonly associated with the technique (Table 4) are usually minor and self-limiting in nature.

Wound contamination by oral bacterial flora following withdrawal of the retrograde guide from the neck is possible and therefore should be removed from the mouth or nasal end wherever possible. The size of cricothyrotomy is larger with the Minitrach (Smith Medical International, Watford, UK) than that created by a needle cricothyrotomy and the contaminated guide can only be removed from the neck. Similarly use of a retrograde guide to pull the tracheal tube or an anterograde guide down the airway could potentially lead to contamination of the wound at the neck.

The translaryngeal plastic cannula may be left in situ as a flexible working channel shielding the wound from possible trauma and infection from manoeuvring of the retrograde guide [13].

There have been a few reports of life threatening upper airway obstruction arising from the cricothyrotomy component of the procedure [84, 86]. In a series of 93 consecutive patients with laryngeal cancer undergoing retrograde intubation for laryngectomy, no damage to the mucus membranes or cartilages was demonstrated in the excised specimens [15].

Administration of oxygen during the procedure

Administration of oxygen is necessary during retrograde intubation as the patient is prone to hypoxia from coughing, laryngospasm, pre-existing or iatrogenic partial

airway obstruction, worsening of respiratory failure from supine positioning or respiratory depressant drugs.

When performed with the patient spontaneously breathing, oxygen may be provided via the nose. Oxygen insufflation through the puncturing needle or through the working channel of a flexible fiberoptic endoscope have been reported [3, 13]. The tracheal tube may be used for oxygen delivery and ventilation when it is engaged in the laryngeal inlet [3, 45]. Intermittent ventilation with facemask between the steps of retrograde intubation may be possible.

Oxygen insufflation or jet ventilation may be carried out through the hollow anterograde device but pulmonary barotrauma is possible in the presence of upper airway obstruction. With a multilumen catheter guide it is possible to monitor airway pressure and capnography via built in channels [14].

Discussion

From the reports of success and safety with the technique it is evident that retrograde intubation has a place in both anticipated as well as the unanticipated pathway in a difficult airway management algorithm [3, 8, 11, 12, 15, 31, 34, 40]. Unlike flexible fiberoptic endoscope guided intubation, retrograde intubation can be performed when blood or secretions are present in the upper airway. Retrograde intubation can also be performed when a patient's neck is immobilised. Retrograde intubation is less invasive than needle cricothyrotomy and surgical cricothyrotomy and in the 'cannot intubate, cannot ventilate' scenario can achieve the primary objective of oxygen delivery to the trachea. The time taken to complete the procedure is short [11–13].

Contraindications include difficult sub glottic access, unfavourable coagulation profile and infection or tumour in the path of access to the larynx.

Retrograde intubation is recommended in the difficult airway algorithm of The American Society of Anesthesiologists (ASA) as an alternative non-invasive method of intubation when there is difficulty with tracheal intubation but the patient's lungs can still be ventilated [89]. The Canadian Society of Anesthesiologists recommends retrograde intubation when ventilation of lungs is not possible [90] (from their algorithm for the management of the difficult airway). The guidelines from The French Society of Anaesthesia and Intensive Care and The Italian Society of Anaesthesia, Resuscitation, and Intensive Therapy (SIAARTI) mention retrograde intubation as an alternative awake intubation technique. Retrograde intubation is not mentioned in the difficult airway algorithms from the Difficult Airway Society (UK) or the German Society of Anaesthesiology and Intensive Care Medicine [91].

Retrograde techniques of intubation are rarely taught or practiced. The reasons for this include unfamiliarity with and the perceived invasive nature of the procedure. Extra training in retrograde intubation has been strongly advised by French anaesthetists responding to a survey, and assessment amongst difficult airway experts [92]. In surveys of equipment for tracheal intubation in anaesthesia [93–97] and emergency departments [98, 99], retrograde intubation kits are commonly stocked but it is difficult to know how frequently they are used. Retrograde intubation has been observed as 'an underused elective or emergency intubation technique in the management of the difficult airway' [100].

Training methods such as audio-visual materials, manikin simulators and cadavers have been suggested for training in retrograde intubation [67]. Patients for laryngectomy without obvious contraindications for retrograde intubation have been used and advocated as a training model [101]. After training on embalmed cadavers, the proportion of residents who reported that they would use retrograde intubation, increased from 6% to 67% and those who reported they could correctly perform the technique increased from 28% to 83% [38].

Retrograde intubation is included in the training curriculum of the Royal College of Anaesthetists in the UK [102].

In difficult intubation situations when the fiberoptic equipment or the expertise to use it is unavailable or blood and secretions rule out its use, early application of retrograde tracheal intubation technique may prevent hypoxia, airway trauma, open cricothyrotomy or tracheostomy anywhere in the world.

Acknowledgements

Author wishes to thank Drs D. Canty and T. Mohler, staff specialist anaesthetists from the Department of Anaesthesia at the Royal Hobart Hospital, Hobart, Tasmania, Australia and EHC Liu, Associate Professor of Anaesthesia, National University of Singapore, Singapore for their suggestions for the manuscript. The cadaver sections were kindly provided by Professor Rajendran, Department of Anatomy, National University of Singapore. Thanks to J. Hanuszewicz from the Teaching and Research Support Unit of University of Tasmania for help with the illustrations.

References

- 1 Waters DJ. Guided blind endotracheal intubation. *Anaesthesia* 1963; **18**: 159–62.
- 2 Powell WF, Ozdil T. A translaryngeal guide for tracheal intubation. *Anesthesia and Analgesia* 1967; **46**: 231–4.
- 3 King HK, Wang LF, Khan AK, Wooten DJ. Translaryngeal guided intubation for difficult intubation. *Critical Care Medicine* 1987; **15**: 869–71.
- 4 Butler FS, Cirillo AA. Retrograde tracheal intubation. *Anesthesia and Analgesia* 1960; **39**: 333.
- 5 Akinyemi OO. Complications of guided blind intubation. *Anaesthesia* 1979; **34**: 590–2.
- 6 Kubo K, Takahashi S, Oka M. A modified technique of guided blind intubation in oral surgery. *Journal of Maxillo-facial Surgery* 1980; **8**: 135–7.
- 7 Dhara SS. Guided blind endotracheal intubation (Correspondence). *Anaesthesia* 1980; **35**: 921.
- 8 Casthely PA, Landesman S, Fyman PN, et al. Retrograde intubation in patients undergoing open heart surgery. *Canadian Anaesthetists' Society journal* 1985; **32**: 661–4.
- 9 Guggenberger H, Lenz G, Heumann H. Success rate and complications of modified guided blind technique for intubation in 36 patients. *Anaesthetist* 1987; **36**: 703–7. (Article in German)
- 10 Harrison CA, Wise CC. Retrograde intubation. *Anaesthesia* 1988; **43**: 609.
- 11 Barriot P, Riou B. Retrograde technique for tracheal intubation in trauma patients. *Critical Care Medicine* 1988; **16**: 712–3.
- 12 Heller EM, Schneider K, Saven B. Percutaneous retrograde intubation. *The Laryngoscope* 1989; **99**: 554–5.
- 13 Audenaert SM, Montgomery CL, Stone B, et al. Retrograde-assisted fiberoptic tracheal intubation in children with difficult airways. *Anesthesia and Analgesia* 1991; **73**: 660–4.
- 14 Dhara SS. Retrograde intubation—a facilitated approach. *British Journal of Anaesthesia* 1992; **69**: 631–3.
- 15 Bissinger U, Guggenberger H, Lenz G. Retrograde-guided fiberoptic intubation in patients with laryngeal carcinoma. *Anesthesia and Analgesia* 1995; **81**: 408–10.
- 16 Hung OR, Al-Qatari M. Light-guided retrograde intubation. *Canadian Journal of Anaesthesia* 1997; **44**: 877–82.
- 17 Grunfeld A, Mihalache A, Berkenstadt H, Segal E, Perel A. A novel technique for retrograde intubation. *European Journal of Anaesthesiology* 2000; **Suppl. 17** (Suppl. 19): 34–5.
- 18 Weksler N, Klein M, Weksler D, et al. Retrograde tracheal intubation: beyond fiberoptic endotracheal intubation. *Acta Anaesthesiologica Scandinavica* 2004; **48**: 412–6.
- 19 Gill M, Madden M, Green SM. Retrograde endotracheal intubation: an investigation of indications, complications and patient outcomes. *American Journal of Emergency Medicine* 2005; **23**: 123–6.
- 20 Parmet JL, Metz S. Anesthesiology issues in general surgery: retrograde endotracheal intubation: an underutilized tool for management of the difficult airway. *Contemporary surgery* 1996; **49**: 300–6.
- 21 Arima H, Sobue K, Tanaka S, et al. Difficult airway in a child with spinal muscular atrophy type I. *Paediatric Anaesthesia* 2003; **13**: 342–4.
- 22 Marciniak D, Smith CE. Emergent retrograde tracheal intubation with a Gum-Elastic Bougie in a trauma patient. *Anesthesia and Analgesia* 2007; **105**: 1720–1.

- 23 Przybylo HJ, Stevenson GW, Vicari FA, et al. Retrograde fibre optic intubation in a child with Nager's syndrome. *Canadian Journal of Anaesthesia* 1996; **43**: 697–9.
- 24 Rosenblatt WH, Angood PB, Maranets I, et al. Retrograde fiberoptic intubation. *Anesthesia and Analgesia* 1997; **84**: 1142–4.
- 25 Seavello J, Hammer GB. Tracheal intubation in a child with trismus pseudocamptodactyly syndrome. *Journal of Clinical Anaesthesia* 1999; **11**: 254–6.
- 26 Borland LM, Swan DM, Leff S. Difficult pediatric endotracheal intubation: a new approach to the retrograde technique. *Anesthesiology* 1981; **55**: 577–8.
- 27 Ramsay MAE, Salyer KE. The management of a child with a major airway abnormality. *Plastic and Reconstructive Surgery* 1981; **67**: 668–70.
- 28 Cooper CMS, Murray-Wilson A. Retrograde intubation (Management of a 4.8-kg, 5 month infant). *Anaesthesia* 1987; **42**: 1197–200.
- 29 Bhardwaj N, Yaddanapudi S, Makkar S. Retrograde tracheal intubation in a patient with a Halo traction device. *Anesthesia and Analgesia* 2006; **103**: 1628–9.
- 30 Payne KA. Difficult tracheal intubation. *Anaesthesia and Intensive Care* 1980; **8**: 84–90.
- 31 Heslet L, Christensen KS, Sanchez R, et al. Facilitated blind intubation using a transtracheal guide wire. *Danish Medical Bulletin* 1985; **32**: 275–7.
- 32 Alfery DD. Double-lumen endobronchial tube intubation using a retrograde wire technique. *Anesthesia and Analgesia* 1993; **76**: 1369–78.
- 33 Roberts KW, Solgonick M. A modification of retrograde wire-guided, fiberoptic-assisted endotracheal intubation in a patient with ankylosing spondylitis. *Anesthesia and Analgesia* 1996; **82**: 1290–1.
- 34 Hines MH, Meredith JW. Modified retrograde intubation technique for rapid airway access. *American Journal of Surgery* 1990; **159**: 597–9.
- 35 Manchester GH, Mani MM, Masters FW. A simple method for emergency oro-tracheal intubation. *Plastic and Reconstructive Surgery* 1972; **49**: 312–5.
- 36 Raza S, Levinsky L, Lazos TZ. Transtracheal intubation. *The Journal of Thoracic and Cardiovascular Surgery* 1978; **76**: 721–2.
- 37 van Stralen DW, Rogers M, Perkin RM, Fea S. Retrograde intubation training using a mannequin. *American Journal of Emergency Medicine* 1995; **13**: 50–2.
- 38 Hatton KW, Price S, Craig L, Grider JS. Educating anaesthesiology residents to perform percutaneous cricothyrotomy, retrograde intubation, and fiberoptic bronchoscopy using preserved cadaver. *Anesthesia and Analgesia* 2006; **103**: 1205–8.
- 39 Shantha TR. Retrograde intubation using the subcricoid region. *British Journal of Anaesthesia* 1992; **68**: 109–12.
- 40 Llewellyn JC, Forrlor M, Pottecher T, Otteni JC. Retrograde intubation using the subcricoid region (Correspondence). *British Journal of Anaesthesia* 1992; **69**: 542–5.
- 41 Shantha TR. Retrograde intubation using the subcricoid region (Correspondence). *British Journal of Anaesthesia* 1992; **69**: 542–5.
- 42 Bennett JD, Guha SC, Sankar AB. Cricothyrotomy; the anatomical basis. *Journal of Royal College of Surgeons of Edinburgh* 1996; **41**: 57–60.
- 43 Roberts KW. New use for Swan-Ganz introducer wire. *Anesthesia and Analgesia* 1981; **60**: 67.
- 44 Gotta AW, Sullivan CA. Anaesthesia of the upper airway using topical anaesthetic and superior laryngeal nerve block. *British Journal of Anaesthesia* 1981; **53**: 1055–8.
- 45 McLean A. Guided blind oral intubation (correspondence). *Anaesthesia* 1982; **37**: 605.
- 46 Gerenstein RI, Arria-Devoe G. J-wire and translaryngeal guided intubation (letter to the editor). *Critical Care Medicine* 1989; **17**: 486.
- 47 Smith DC. Emergency guided blind intubation. *Anaesthesia* 1986; **41**: 1264.
- 48 Slots P, Vegger PB, Bettger H, Reinstrup P. Retrograde intubation with a Mini-Trach II kit. *Acta Anaesthesiologica Scandinavica* 2003; **47**: 274–7.
- 49 McNamara RM. Retrograde intubation of the trachea. *Annals of Emergency Medicine* 1987; **16**: 680–2.
- 50 Scurr C. A complication of guided blind intubation (Correspondence). *Anaesthesia* 1975; **30**: 411–2.
- 51 Arya VK, Dutta A, Chari P, Sharma RK. Difficult retrograde endotracheal intubation: the utility of a pharyngeal loop. *Anesthesia and Analgesia* 2002; **94**: 470–3.
- 52 Bhattacharya P, Biswas BK, Baniwal S. Retrieval of a retrograde catheter using suction, in patients who cannot open their mouths. *British Journal of Anaesthesia* 2004; **92**: 888–90.
- 53 Biswas BK, Bhattacharya P, Joshi S, et al. Fluoroscope-aided retrograde placement of guide wire for tracheal intubation in patients with limited mouth opening. *British Journal of Anaesthesia* 2005; **94**: 128–31.
- 54 Asai T, Shingu K. Difficulty in advancing a tracheal tube over a fiberoptic bronchoscope: incidence, causes and solutions. *British Journal of Anaesthesia* 2004; **92**: 870–81.
- 55 Johnson DM, From AM, Smith RB, From RP, Maktabi MA. Endoscopic study of mechanisms of failures of endotracheal tube advancement into the trachea during awake fiberoptic oro-tracheal intubation. *Anesthesiology* 2005; **102**: 910–4.
- 56 Marfin AG, Iqbal R, Mihm F, et al. Determination of the site of tracheal tube impingement during nasotracheal fiberoptic intubation. *Anaesthesia* 2006; **61**: 646–50.
- 57 Cossham PS. Difficult intubation. *British Journal of Anaesthesia* 1985; **57**: 239.
- 58 Dogra S, Falconer R, Latta IP. Successful difficult intubation. Tracheal tube placement over a gum elastic bougie. *Anaesthesia* 1990; **45**: 774–6.
- 59 Shearer AJ, McGuire BE. Railroaded tracheal tubes over a fibroscope. *Anaesthesia* 2006; **61**: 1222.
- 60 Hakala P, Randell P. Comparison between two fibrescopes with different diameter insertion cords for fiberoptic intubation. *Anaesthesia* 1995; **50**: 735–7.

- 61 Brull SJ, Wiklund R, Ferris C, et al. Facilitation of fibre optic orotracheal intubation with a flexible tracheal tube. *Anesthesia and Analgesia* 1994; **78**: 746–8.
- 62 Kristensen MS. The Parker Flex-tip versus a standard tube for fiberoptic oro-tracheal intubation: a randomised double-blind study. *Anesthesiology* 2003; **98**: 354–8.
- 63 Makino H, Katoh T, Kobayashi S, Bito H, Sato S. The effects of tracheal tube tip design and tube thickness on laryngeal pass ability during oral tube exchange with an introducer. *Anesthesia and Analgesia* 2003; **97**: 285–8.
- 64 Bourke D, Levesque PR. Modification of retrograde guide for endotracheal intubation. *Anesthesia and Analgesia* 1974; **53**: 1013–4.
- 65 Copley M, Vaughan RS. Recognition and management of difficult airway problems. *British Journal of Anaesthesia* 1992; **68**: 90–7.
- 66 Joo HS, Kataoka MT, Chen RJB, Doyle J, Mazer CD. PVC tracheal tubes forces and pressures seven to ten times higher than silicone or armoured tracheal tubes – an in vitro study. *Canadian Journal of Anaesthesia* 2002; **49**: 986–9.
- 67 Wijesinghe HS, Gough JE. Complications of a retrograde intubation in a trauma patient. *Academic Emergency Medicine: Official Journal of The Society for Academic Emergency Medicine* 2000; **7**: 1267–71.
- 68 Harmer M, Vaughan RS. Guided blind oral intubation. *Anaesthesia* 1980; **35**: 921.
- 69 Latto IP, Vaughan RS, eds. *Management of difficult intubation; Difficulties in tracheal intubation*. London: W B Saunders Company Ltd, 1997.
- 70 Abu-Madi MN, Trop D. Pulling versus guiding: a modification of retrograde guided intubation. *Canadian Journal of Anaesthesia* 1989; **36**: 336–9.
- 71 Mahajan R, Sandhya X, Chari P. An alternative technique for retrograde intubation. *Anaesthesia* 2001; **56**: 1203–4.
- 72 Freund PR, Rooke A, Schmid H. Retrograde intubation with a modified Eschmann stylet. *Anesthesia and Analgesia* 1988; **67**: 605–6.
- 73 Leissner KB. Retrograde intubation with epidural catheter and Cook airway exchange catheter. *Canadian Journal of Anaesthesia* 2007; **54**: 400–1.
- 74 Spencer RF, Rathmell JP, Viscomi CM. A new method for difficult endotracheal intubation: the use of a jet stylet introducer and capnography. *Anesthesia and Analgesia* 1995; **81**: 1079–83.
- 75 Sinclair JR, Mason RA. Ankylosing spondylitis. The case for awake intubation. *Anaesthesia* 1984; **39**: 3–11.
- 76 Tobias R. Increased success with retrograde guide for endotracheal intubation. *Anesthesia and Analgesia* 1983; **62**: 366–7.
- 77 Eidelman LA, Pizov R, Bissinger U, Guggenberger H, Lenz G. A safer approach to retrograde-guided fiberoptic intubation (Correspondence). *Anesthesia and Analgesia* 1996; **82**: 1108.
- 78 Lenfant F, Benkhadra M, Trouilloud P, Freysz M. Comparison of two techniques for retrograde tracheal intubation in human fresh cadavers. *Anesthesiology* 2006; **104**: 48–51.
- 79 Carlson CA, Perkins HM, Veltkamp S. Solving a difficult intubation (Correspondence). *Anesthesiology* 1986; **64**: 537–8.
- 80 Lechman MJ, Donahoo JS, Macvaugh H. Endotracheal intubation using percutaneous retrograde guidewire insertion followed by antegrade fiberoptic bronchoscopy. *Critical Care Medicine* 1986; **14**: 589–90.
- 81 Gupta B, McDonald JS, Brooks JHJ, Mendenhall J. Oral fiberoptic intubation over a retrograde guidewire. *Anesthesia and Analgesia* 1989; **68**: 517–9.
- 82 Harvey SC, Fishman RL, Edwards S. Retrograde intubation through a Laryngeal Mask Airway. *Anesthesiology* 1996; **85**: 1503–4.
- 83 Arndt GA, Topp J, Hannah J, McDowell TS, Lesko A. Intubation via the LMA using a Cook retrograde intubation kit. *Canadian Journal of Anaesthesia* 1998; **45**: 257–60.
- 84 Akinyemi OO, John A. A complication of guided blind intubation. *Anaesthesia* 1974; **29**: 733–5.
- 85 Poon YK. Case history number 89: a life threatening complication of cricothyroid membrane puncture. *Anesthesia and Analgesia* 1976; **55**: 298–301.
- 86 Contrucci RB, Gottlieb JS. A complication of retrograde endotracheal intubation. *Ear, Nose and Throat Journal* 1990; **99**: 776–8.
- 87 Bowes WA, Johnson JO. Pneumomediastinum after planned retrograde fiberoptic intubation. *Anesthesia and Analgesia* 1994; **78**: 795–7.
- 88 Beebe DS, Tran P, Belani K, Adams GL. Pretracheal abscess following retrograde tracheal intubation. *Anaesthesia* 1995; **50**: 470.
- 89 American Society of Anesthesiologists Task Force on Management of the Difficult Airway. Practice guidelines for management of the difficult airway. an updated report by the American Society of Anesthesiologists Task Force on Management of the Difficult Airway. *Anesthesiology* 2003; **98**: 1269–77.
- 90 Crosby ET, Cooper RM, Douglas J, Doyle J, et al. The unanticipated difficult airway with recommendations for management. *Canadian Journal of Anaesthesia* 1998; **45**: 757–76.
- 91 Heidegger T, Gerig HJ, Henderson JJ. Strategies and algorithms for management of the difficult airway. *Best Practice & Research. Clinical Anaesthesiology* 2005; **19**: 661–74.
- 92 Avargues P, Cros AM, Daucourt V, Michel P, Maurette P. Procedures used by French anaesthetists in cases of difficult intubation and impact of a conference of experts. *Annales Françaises d'Anesthésie et de Réanimation* 1999; **18**: 719–24.
- 93 Rosenblatt WH, Wagner PJ, Ovassapian A, Kain ZN. Practice patterns in managing the difficult airway by anesthesiologists in the United States. *Anesthesia and Analgesia* 1998; **87**: 153–7.
- 94 Ezri T, Konichezky S, Geva D, et al. Difficult airway management patterns among attending anaesthetists practising in Israel. *European Journal of Anaesthesiology* 2003; **20**: 619–23.
- 95 Ezri T, Szmuk P, Wartens RD, Katz J, Hagberg CA. Difficult airway management practice patterns among

- anesthesiologists practicing in the United States: have we made any progress? *Journal of Clinical Anaesthesia* 2003; **15**: 418–22.
- 96 Mellado PF, Thunedborg LP, Swiatek F, Kristensen MS. Anaesthesiological airway management in Denmark: assessment, equipment, and documentation. *Acta Anaesthesiologica Scandinavica* 2004; **48**: 350–4.
- 97 Goldmann K, Braun U. Airway management practices at German university and university – affiliated teaching hospitals- equipment, techniques and training: results of a nationwide survey. *Acta Anaesthesiologica Scandinavica* 2006; **50**: 298–305.
- 98 Levitan RM, Kush S, Hollander JE. Devices for difficult airway management in academic emergency departments: results of a national survey. *Annals of Emergency Medicine* 1999; **33**: 694–8.
- 99 Reeder TJ, Brown CK, Norris DL. Managing the difficult airway: a survey of residency directors and a call for change. *The Journal of Emergency Medicine* 2005; **28**: 473–8.
- 100 Benumof JL. Management of the difficult adult airway. *Anesthesiology* 1991; **75**: 1087–110.
- 101 Guggenberger H, Lenz G. Training in retrograde intubation. *Anesthesiology* 1988; **69**: 292.
- 102 Royal College of Anaesthetists. CCST in Anaesthesia III, Edition 2; April, 2003. Section 7: Generic Knowledge and skills page III – 11–13. <http://www.rcoa.ac.uk> (accessed May 2006).