Bedside Ultrasonography Evaluation of Shock

Joshua D. Farkas, MD[a,*], Mireille K. Anawati, MD[b]

KEYWORDS

• Ultrasonography • Pericardial effusion • Tamponade
• Left ventricular ejection fraction • Pulmonary embolism • Septal flattening
• Inferior vena cava • Right ventricular dilation

HOSPITAL MEDICINE CLINICS CHECKLIST

1. Adequately trained clinicians can interpret information from bedside ultrasonography to refine their diagnostic and therapeutic approach to patients in shock.
2. Clinician ultrasonography is not intended to replace formal echocardiography, but is intended to answer simple questions in the evaluation of a patient in shock.
3. The primary limitation to clinician ultrasonography is difficulty obtaining adequate images.
4. Some causes of shock may be difficult to detect based on traditional evaluation and may be revealed only by echocardiogram.
5. Ultrasonography assessment of inferior vena cava, lungs, pericardial fluid, left ventricle, right ventricle, and valves can help to classify shock states.
6. Pericardial tamponade is suggested by the combination of a large pericardial effusion, a dilated inferior vena cava, and lack of another explanation for the patient's shock.
7. A normal ejection fraction or hyperkinetic left ventricle excludes cardiomyopathy as a cause of shock.
8. End-systolic left ventricular obliteration usually reflects either hypovolemic shock or early septic shock.

CONTINUED

Disclosure statement: Neither Dr J.D. Farkas nor Dr M.K. Anawati has any relevant financial or nonfinancial relationships to disclose.

[a] Division of Pulmonary and Critical Care Medicine, University of Vermont Medical Center, Burlington, VT 05401, USA; [b] Section of Hospital Medicine, University of Vermont Medical Center, Burlington, VT 05401, USA
* Corresponding author.
E-mail address: joshua.farkas@med.uvm.edu

Hosp Med Clin ■ (2015) ■–■
http://dx.doi.org/10.1016/j.ehmc.2014.11.004
2211-5943/15/$ – see front matter © 2015 Elsevier Inc. All rights reserved.

CONTINUED

9. Massive pulmonary embolism is invariably associated with right ventricular dilatation.
10. Septal flattening may be an adjunctive sign suggesting hemodynamically significant right ventricular failure.
11. Inferior vena cava size and jugular venous distention may be helpful in assessing the volume status of a patient in shock.
12. In patients with cardiogenic shock and increased pulmonary capillary wedge pressure, a diffuse pattern of B lines throughout the lungs is generally seen.
13. Lack of lung slide or B lines raises concern for pneumothorax.
14. Regurgitation across the mitral or aortic valves raises concerns for diagnoses such as endocarditis, acute myocardial infarction with ruptured chordae tendineae, or aortic dissection.
15. Multifactorial shock confounds simple categorization schemes and may be suggested by discordant findings.
16. One of the more challenging distinctions to make with clinician ultrasonography is differentiating hypovolemic shock from septic shock.

OVERVIEW

The availability of clinician ultrasonography has revolutionized the bedside approach to patients in shock. New-onset shock is a medical emergency requiring prompt and definitive therapy. The differential diagnosis is broad, and every entity on the differential diagnosis is life-threatening and requires specific therapy. Time is of the essence and, for patients in extremis, even minutes may count. Clinician echocardiography provides a fast and safe window into the physiology of shocked patients. Although not every patient can be imaged with ultrasonography, in most patients it assists in the categorization of the type of shock.

With regard to the technical aspects of imaging the heart, the reader is referred to a recent article in *Critical Care Clinics* on echocardiography.[1] This article focuses on how clinicians may integrate findings from the ultrasonographic examination when evaluating a patient with shock.

INTRODUCTION TO CLINICIAN SHOCK ULTRASONOGRAPHY

Who should perform bedside ultrasonography?

In the past, echocardiography was performed solely by trained technologists and interpreted by cardiologists. Although a formal echocardiogram is the most complete and definitive approach, it is frequently unavailable and has an associated time delay. Shock is a true medical emergency and the so-called golden hour of intervention does not wait for an official echocardiogram.

Based on the necessity of immediate information and advances in ultrasonography technology, clinician echocardiography has grown into a well-accepted practice. In this case ultrasonography is performed at the bedside by the treating clinician, which eliminates delays in imaging acquisition and interpretation and also allows the treating physician to appreciate the quality of information being obtained. It has been shown that acquiring skills in basic echocardiography is achievable, with performance at answering simple questions approaching that of formal echocardiography.[2]

How does clinician ultrasonography differ from formal echocardiography?

Unlike formal echocardiography, which provides a more complete description of cardiac structure and function, clinician ultrasonography is focused on answering a small number of simple questions in the evaluation of shock:

1. Is a significant pericardial effusion present?
2. Is the left ventricular ejection fraction (LVEF) severely impaired?
3. Is the right ventricle (RV) significantly dilated?
4. What is the size of the inferior vena cava (IVC)?
5. What is the pattern of ultrasonography artifact in the lungs?
6. Is there significant valvular regurgitation across the mitral or aortic valves?

Clinician ultrasonography is not intended to replace formal echocardiography. Often a formal echocardiogram is obtained to confirm and document findings detected on clinician ultrasonography. If there is a concern for critical findings (eg, tamponade or severe valvular regurgitation) this may prompt an urgent formal echocardiogram as well as a cardiology consultation.

What are the limitations of clinician ultrasonography?

The primary limitation to clinician ultrasonography is difficulty obtaining adequate images because of suboptimal sonographic windows. Hyperinflation of the lungs, bowel gas, obesity, and limitations in positioning patients may all render imaging difficult. The bedside study may have definitive results, it may be suggestive of an abnormality, or it may be impossible to obtain any interpretable views.

Ultimately clinician ultrasonography is intended to supplement (rather than replace) other clinical information, including the history and physical and any available laboratory and imaging studies. Bedside clinicians must assess the quality of images and the consistency of findings across various sonographic views, and must exercise judgment in combining this information with other data.

How does clinician ultrasonography help in the assessment of patients with new-onset shock?

Experienced clinicians are able to ascertain the cause of shock in most patients based on history and physical examination. The most common types of shock in hospitalized patients are hypovolemic shock and septic shock, which are often suggested by history and other associated signs. However, some causes of shock may be difficult to detect based on traditional evaluation and may be revealed only by echocardiogram. The most common cardiac causes are cardiomyopathy (often viral myocarditis or postpartum cardiomyopathy), and pericardial tamponade,[3] although pulmonary embolism must also be considered. In our experience, a few cases of unsuspected tamponade and pulmonary embolism are disclosed by clinician ultrasonography every year.

What advantages does clinician ultrasonography have compared with Swan-Ganz catheterization?

Previously, Swan-Ganz catheterization was often used to differentiate among various causes of shock. Swan-Ganz catheterization has numerous drawbacks: exposing patients to the risks of an invasive procedure, requiring transportation to an intensive care unit, and consuming significant time. Furthermore, the data obtained often do not

reveal a specific diagnosis. Clinician ultrasonography has largely replaced Swan-Ganz catheterization because it is faster, safer, more portable, and often yields a specific diagnosis.

CLINICIAN SHOCK ULTRASONOGRAPHY: COMPONENTS

Is there an algorithmic approach to clinician shock ultrasonography?

One potential pitfall of clinician ultrasonography is that, if the clinician has a strong pretest probability for a certain diagnosis, this could lead to performing an incomplete examination and missing an alternative diagnosis. Therefore, it is useful to have a systematic approach that attempts to identify the following structures on every patient:

- Pericardial effusion
- LVEF
- Dilatation of the RV
- IVC size (if unobtainable, then evaluate jugular vein pressure)
- Mitral and aortic valve regurgitation
- Anterior lung ultrasonography

Abnormalities found on this examination may lead clinicians to add on additional ultrasonography examinations. For example, if RV size raises a concern for pulmonary embolism, a deep vein thrombosis examination may help evaluate for pulmonary embolism. Alternatively, if the anterior lung ultrasonography suggests pneumonia, a more complete examination of the lungs and pleura may be useful.

How can bedside echocardiography evaluate for pericardial tamponade?

Clinician echocardiography is excellent to exclude or suggest the diagnosis of tamponade. The hallmarks of tamponade are a significant pericardial effusion and a dilated IVC. In general, tamponade is associated with a large, circumferential pericardial effusion (**Fig. 1**). One notable exception is tamponade caused by hemopericardium following cardiac surgery or interventional cardiac procedures, in which case rapid

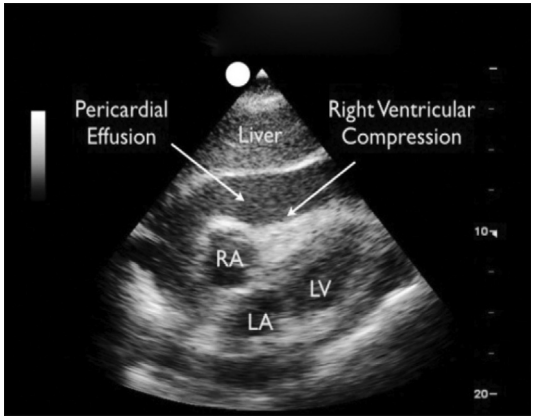

Fig. 1. A large pericardial effusion is seen on subxiphoid view with diastolic collapse of the RV. LA, left atrium; LV, left ventricle; RA, right atrium. (*From* Goodman A, Perera P, Milhot T, et al. The role of bedside ultrasound in the diagnosis of pericardial effusion and cardiac tamponade. J Emerg Trauma Shock 2012;5(1):72–5.)

accumulation of a loculated collection of blood may cause tamponade without being obvious on echocardiography.

Dilatation of the IVC is sensitive for tamponade but is nonspecific. In the absence of IVC dilatation, a diagnosis of tamponade must be questioned. Thus, tamponade is suggested by the combination of a large pericardial effusion, a dilated IVC, and lack of another explanation for the patient's shock. Diastolic collapse of the right-sided chambers may suggest tamponade, although this has imperfect sensitivity. If there is significant concern for pericardial tamponade, emergent formal echocardiogram and cardiology consultation should be obtained.

Is the LVEF severely impaired?

Similar to evaluation of the RV, evaluation of the LVEF is more useful in excluding this as a cause of shock. A normal ejection fraction or increased (hyperkinetic) ejection fraction allows exclusion of cardiomyopathy as a cause of shock. The most common technique for assessing LVEF uses a global visual assessment in 2 or 3 views. In general, LVEF can be categorized as hyperdynamic, normal, moderately reduced, or severely reduced. A reduced ejection fraction raises a question of shock caused by cardiomyopathy (most commonly acute myocardial infarction, myocarditis, septic cardiomyopathy, or postpartum cardiomyopathy). However, a reduced ejection fraction may also be a chronic feature, and with current medical therapies there is an increasing population of patients with good performance status despite chronically low ejection fraction. It should be noted that, to cause shock, the ejection fraction typically must be severely reduced; if the LVEF is moderately reduced, another cause of shock should be sought. Comparison with prior imaging studies and history may be helpful in determining whether a reduced LVEF is a chronic or acute feature.

What is the significance of an increased LVEF?

LVEF varies in a dynamic fashion depending on preload, afterload, and contractility. Occasionally a patient is noted to have a substantially increased LVEF with near complete obliteration of the left ventricular cavity during systole. End-systolic left ventricular obliteration usually reflects either severe hypovolemic shock or early septic shock (which may reduce preload because of third spacing of fluid and also reduce afterload because of systemic vasodilatation). Such patients generally respond well to volume resuscitation. However, this must be differentiated from patients with acute cor pulmonale or pericardial tamponade, in whom increase of the LVEF is associated with RV dilatation or pericardial effusion, respectively.

Is the RV significantly dilated?

When using clinician ultrasonography to evaluate for pulmonary embolism as a cause of shock, clinicians are searching for a massive pulmonary embolism. Massive pulmonary embolism is invariably associated with RV dilatation (**Fig. 2**), and as such an RV of normal size allows exclusion of pulmonary embolism as a cause of shock. It should be emphasized that a normal right ventricular size does not exclude a small pulmonary embolism.

In the apical 4-chamber view, RV size may be underestimated if the probe is rotated out of the true 4-chamber axis. Therefore, care should be taken to rotate the probe until the right ventricular size is maximized. The subcostal 4-chamber view is also useful to assess right ventricular size, but similarly care must be taken to fan through the

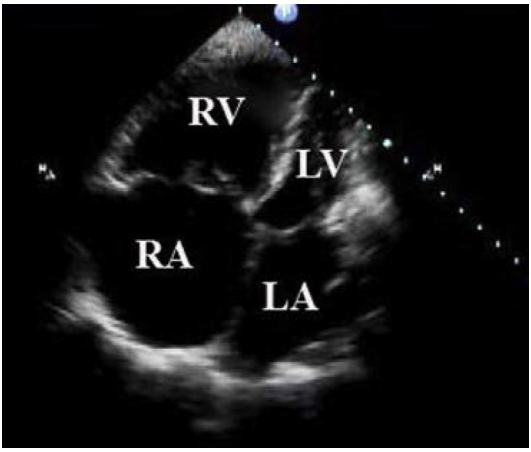

Fig. 2. Right ventricular dilatation (right ventricle/left ventricle ratio >1:1) in this apical 4-chamber image of a patient with an acute pulmonary embolism. (*From* Dresden S, Mitchell P, Rahimi L, et al. Right ventricular dilatation on bedside echocardiography performed by emergency physicians aids in the diagnosis of pulmonary embolism. Ann Emerg Med 2014;63(1):16–24; with permission.)

entire right ventricle to avoid underestimating its size.[4] The RV is considered dilated if it appears larger than the left ventricle.

Moreover, the differential diagnosis for right ventricular dilatation includes right ventricular myocardial infarction or (more often) chronic pulmonary hypertension. Clinical correlation as well as comparison with prior thoracic computed tomography (CT), echocardiographic data, and electrocardiographic data may be helpful in assessment of chronic pulmonary hypertension. Clinician ultrasonography of the deep veins showing a deep vein thrombosis supports a diagnosis of pulmonary embolism.

How does septal shift assist in evaluation of right ventricular dilatation?

Normally, in the short-axis configuration, the interventricular septum bulges to the right such that the left ventricle has circular shape, whereas the RV assumes a crescent shape. With right ventricular pressure overload as caused by pulmonary embolism, the septum initially flattens, assuming a D configuration. With severe pressure overload, the septum may invert into the left ventricle such that the RV assumes a circular configuration and the left ventricle is forced into a crescent. The mechanism of shock caused by pulmonary embolism is largely caused by this effect of the septum on restricting left ventricular filling. As such, septal flattening (and especially inversion into the left ventricle) may be an adjunctive sign suggesting hemodynamically significant right ventricular failure (**Fig. 3**).

What is the size of the IVC?

A commonly used method to obtain IVC measurements is to obtain an image with the probe in the subxiphoid region, measuring its size at end-expiration just proximal to the junction of the IVC and hepatic veins. Central venous pressure (CVP) correlates with the size of the IVC. Respirophasic variation in the IVC diameter (>50% with an intentional sniff maneuver, or lesser degrees with passive ventilation) suggests a low CVP (**Figs. 4** and **5**, **Table 1**).

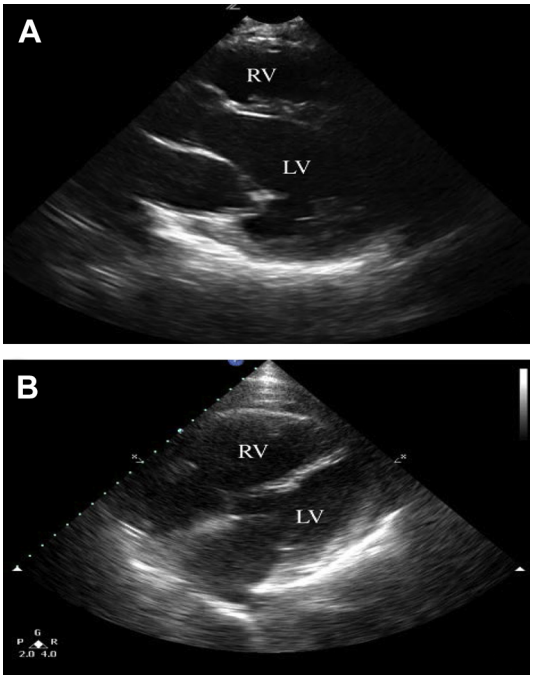

Fig. 3. Parasternal long axis views of the heart; (*A*) Demonstrates normal RV:LV ratio in a normal heart without right ventricular strain; (*B*) Demonstrates RV strain with an RV:LV ratio greater than 1. (*From* Taylor RA, Davis J, Liu R, et al. Point-of-care focused cardiac ultrasound for prediction of pulmonary embolism adverse outcomes. J Emerg Med 2013;45(3):392–9; with permission.)

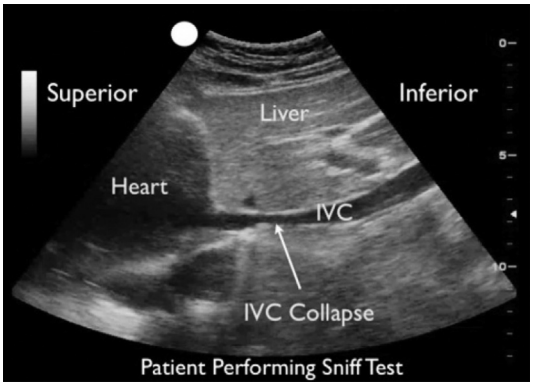

Fig. 4. The presence of a small IVC with greater than 50% collapse on forced inspiration, or sniff, correlates with a low CVP. (*From* Goodman A, Perera P, Milhot T, et al. The role of bedside ultrasound in the diagnosis of pericardial effusion and cardiac tamponade. J Emerg Trauma Shock 2012;5(1):72–5.)

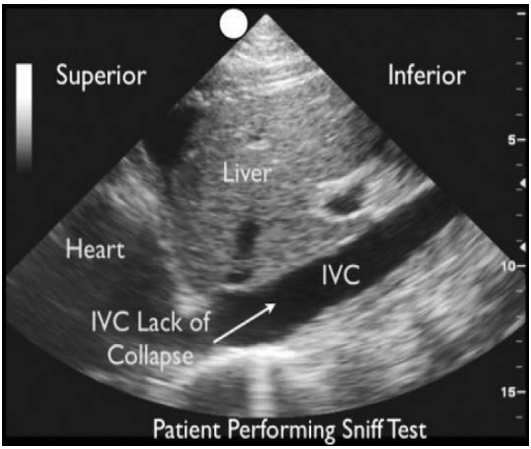

Fig. 5. The presence of a dilated IVC with less than 50% collapse on forced inspiration, or sniff, correlates with an increased CVP. (*From* Goodman A, Perera P, Milhot T, et al. The role of bedside ultrasound in the diagnosis of pericardial effusion and cardiac tamponade. J Emerg Trauma Shock 2012;5(1):72–5.)

There are a variety of classification schemes for predicting the CVP from an echocardiographic examination. The American Society of Echocardiography guidelines recommend an approach that combines IVC diameter and respiratory variability (see **Table 1**).[5]

If the IVC cannot be visualized from the subxiphoid location, an alternative approach is to view it with an anterior midaxillary longitudinal approach using the liver as an acoustic window.[6]

Intubation with positive intrathoracic pressure tends to distend the IVC. In an intubated patient, a small IVC is more specific but less sensitive for intravascular volume depletion. A dilated IVC is harder to interpret in this setting. Alternatively, IVC size may be decreased in the setting of intra-abdominal compartment syndrome.

When approaching a patient with shock of unknown origin, the primary utility of IVC examination is to evaluate for hypovolemic shock, which should be associated with a small IVC. As discussed later, early septic shock may mimic this pattern with a small IVC as well. A normal or dilated IVC argues strongly against hypovolemic shock. For example, in a patient admitted with gastrointestinal bleeding who subsequently develops shock, a dilated IVC suggests that the patient is unlikely to have recurrent hemorrhage but may be experiencing a myocardial infarction or pulmonary embolism as a complication of hospitalization.

How can a clinician confidently estimate CVP if the IVC cannot be visualized?

If it is difficult to visualize the IVC, ultrasonography measurement of the jugular venous pressure (JVP) may be used to estimate CVP. Although JVP may be measured using a

Table 1
Estimating CVP (mm Hg) based on IVC size and respiratory variation

	IVC<2.1 cm	IVC>2.1 cm
Respiratory variation present	CVP 0–5	CVP 5–10
Respiratory variation absent	CVP 5–10	CVP 10–20

traditional physical examination, this may be difficult in patients with subtle jugular venous pulsation. In addition, patients with severely increased CVP may lack a discernable JVP wave because their jugular veins are continually distended; such patients may be misdiagnosed as having a low JVP.

Application of a linear ultrasonography probe to the neck with minimal pressure may reveal whether the jugular vein is distended and the level at which it collapses. This finding correlates well with the CVP, although it tends to slightly underestimate the CVP.[7] In our experience, this is less subjective than attempting to discern the JVP by traditional examination.

What is the pattern of ultrasonography artifact in the lungs?

The primary utility of lung ultrasonography in evaluation of shock is evaluation of the pulmonary capillary wedge pressure. Ultrasonography of the anterior lung fields generally discloses one of 2 patterns of artifacts: A lines or B lines.

A lines are reverberation artifacts of the pleural line, which indicate either normally aerated lung tissue or pneumothorax (**Fig. 6**). B lines (also called comet-tail artifacts) indicate incompletely aerated lung tissue in apposition to the chest wall with a broad differential diagnosis (including cardiogenic or noncardiogenic pulmonary edema, pneumonia, and interstitial lung disease). In patients with cardiogenic shock and increased pulmonary capillary wedge pressure, a diffuse pattern of B lines throughout the lungs is generally seen. B lines are very sensitive for cardiogenic pulmonary edema and may be seen before changes in lung auscultation or definite abnormality on chest radiograph. However, a diffuse B-line pattern may also be seen with diffuse noncardiogenic pulmonary edema and thus is incompletely specific for increased pulmonary

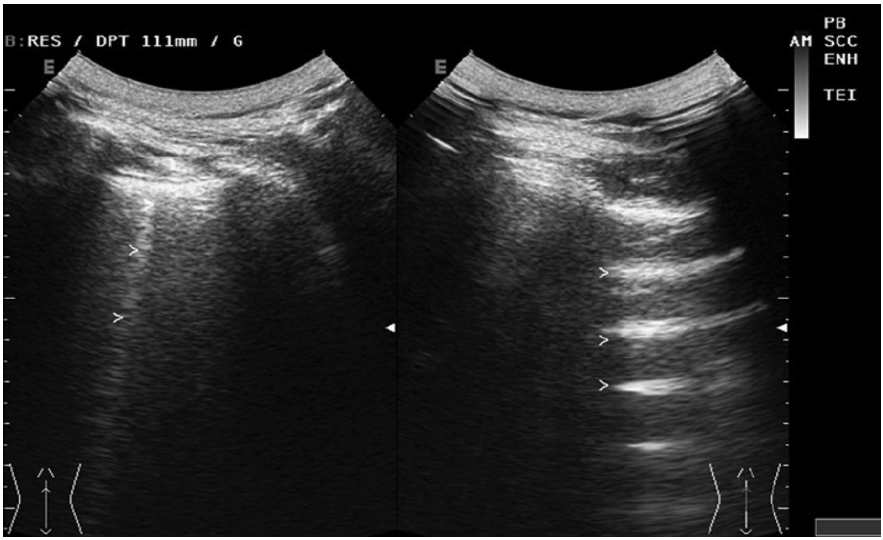

Fig. 6. On the left, B lines are seen as vertical lines that originate at the pleural line. On the right, A lines are seen as horizontal reverberations that are parallel to the pleural line. (*From* Sperandeo M, Rotondo A, Guglielmi G, et al. Transthoracic ultrasound in the assessment of pleural and pulmonary diseases: use and limitations. Radiol Med 2014;119(10):729–40; with permission.)

capillary wedge pressure. Alternatively, if the patient has A lines present bilaterally, this suggests normally aerated lungs with a low or normal pulmonary capillary wedge pressure.[8] Areas of normally aerated lung tissue (with A lines) interspersed with areas of diseased lung (with B lines) suggest pneumonia or other focal pulmonary disorders with a low or normal pulmonary capillary wedge pressure. It should be noted that this discussion only applies to the anterior lung fields, because B lines are frequently found in the dependent lungs of hospitalized patients caused by atelectasis and are nonspecific in this location.

Lung ultrasonography is less intuitive than cardiac ultrasonography and is omitted in many ultrasonography protocols for evaluation of shock. However, it has been shown to add value to the shock evaluation and should not be ignored.[9] It may be particularly helpful in patients with challenging echocardiographic windows, because the lung can always be viewed regardless of body habitus.

How can lung ultrasonography be used to evaluate for pneumothorax?

Although tension pneumothorax is an uncommon cause of shock, it is important not to overlook it given that it mandates immediate and lifesaving therapy. Ultrasonography examination is rapid and has been proved to be more sensitive than chest radiography for the presence of pneumothorax.[10] In supine patients, bilateral lung ultrasonography of the anterior thorax slightly cephalad to the breasts generally allows pneumothorax to be excluded. Lung slide indicates that the visceral pleura is in apposition to the chest wall. Visualization of B lines also excludes pneumothorax because this proves the apposition of lung with the chest wall. Lack of lung slide or B lines raises concern for pneumothorax but is not completely specific: other causes of absent lung slide include prior pleurodesis or low tidal volumes.

An interface between normal lung slide and absence of lung slide is called the lung point and is highly specific for pneumothorax. The location of lung point reflects the size of the pneumothorax (more anterior lung point is consistent with a small pneumothorax, whereas more posterior lung point is consistent with a larger pneumothorax).

It should be noted that in tension pneumothorax there may be no lung point because the entire lung may be collapsed. For further discussion of ultrasonography techniques for evaluation of pneumothorax the reader is referred to additional resources.[11]

Is there significant valvular regurgitation across the mitral or aortic valves?

Acute shock caused by valvular heart disease is almost invariably caused by regurgitation (as opposed to stenosis, which is a chronic process). Qualitative detection of regurgitation using color Doppler imaging is not difficult. However, quantifying the significance of the regurgitation is challenging, and it is common to overestimate the significance of what is actually mild regurgitation. The parasternal long-axis view allows rapid evaluation for mitral and aortic regurgitation. This examination must be regarded as a screening examination only and any suspected abnormality should prompt expert consultation.

Endocarditis may cause shock because of acute regurgitation across the mitral or aortic valves. Patients with acute myocardial infarction are at risk for acute mitral regurgitation and shock from ruptured chordae tendineae. The presence of aortic regurgitation should also raise concern regarding aortic dissection, especially if the aortic root is dilated.

CLINICIAN SHOCK ULTRASONOGRAPHY: INTEGRATION

How can ultrasonography be used to classify patients into different types of shock states?

The ultrasonography assessment of IVC, lungs, pericardial fluid, left ventricle, RV, and valves can help to classify shock states (Table 2). It should be noted that this table does not include some less common causes of shock (eg, auto–positive end-expiratory pressure, abdominal compartment syndrome) that are likely to be suggested by the clinical situation.

Some algorithms for determining the cause of shock focus on sequential exclusion of different causes (ie, first excluding tamponade, second excluding pneumothorax, and so forth). One limitation of this approach is that an abnormality found early during the algorithm could lead to premature diagnostic closure (eg, an insignificant pericardial effusion could lead the clinician to terminate the examination before discovering the true problem). In order to maximize the integrative power of ultrasonography it is best to perform as complete an examination as possible.

Table 2
Classification of shock using ultrasonography findings

	IVC (JVP)	Lungs[a]	Large Pericardial Effusion?	RV Dilatation?	LVEF?	Valvular Regurgitation?
Hypovolemic shock	↓	A lines	No	No	nl/↑	No
Distributive shock, eg: • Septic shock • Adrenal crisis • Anaphylaxis	↓/nl	A lines	No	No	nl/↑[b]	No
RV failure, eg: • PE • RV infarction	↑	A lines	No	Yes	nl/↑	No
Tamponade	↑	A lines	Yes	No	nl/↑	No
Tension pneumothorax	↑	Pneumothorax	No[c]	No[c]	nl/↑[c]	No[c]
Cardiomyopathy	nl/↑	Bilateral B lines	No	No	↓↓	±
Valvular regurgitation	nl/↑	Bilateral B lines	No	No	nl/↑	Yes

Abbreviations: nl, normal; PE, pulmonary embolism.

[a] Other patterns (eg, focal B lines or lung consolidation) may be caused by primary lung disorders such as pneumonia. Noncardiogenic pulmonary edema or chronic interstitial lung disease may cause a pattern of bilateral B lines.

[b] In late septic shock, it is common to develop a septic cardiomyopathy with reduced LVEF.

[c] Pneumothorax (especially left sided) may render echocardiography difficult or impossible by interposing air between the thorax and heart. A heart that was previously visible on echocardiography and subsequently cannot be imaged raises concern for pneumothorax or pneumomediastinum. The diagnosis of pneumothorax is predominantly based on lung ultrasonography.

What are limitations to using ultrasonography to classify patients into different shock states?

Ultrasonographic categorization into shock states is most accurate in young patients with acute-onset shock of a single cause who do not have any underlying disorders. In elderly patients or patients with underlying medical problems, there is an increasing likelihood of chronic abnormalities (eg, reduced LVEF or chronic pulmonary hypertension) that may masquerade as acute problems and confuse the clinical examination.

Patients of any age may have multifactorial shock (most commonly hypovolemia plus another cause), which confounds any simple categorization scheme. The astute clinician may recognize multifactorial shock from discordant ultrasonography findings. For example, consider a patient found to have a severely reduced LVEF and also a small IVC. This patient does not neatly fit into any of the categories in **Table 2**. Discordant findings suggest the combination of 2 problems; for example, chronic systolic heart failure combined with volume depletion caused by excessive diuresis.

In situations in which the contribution of hypovolemia is unclear, fluid challenge with serial ultrasonography evaluation may be helpful. If the patient has hypovolemic shock without ongoing fluid loss, volume resuscitation typically resolves the shock state. Alternatively, if volume resuscitation succeeds in increasing the IVC to a normal size but the patient has persistent shock, an alternative cause should be sought. For example, we once treated a shocked patient with gastroenteritis and known pulmonary emboli with moderate right ventricular dilatation as revealed by CT angiography of the chest. The question arose as to whether to treat the patient with thrombolytics given the presence of pulmonary emboli and shock. However, the patient's IVC was small and collapsible, which was discordant with acute cor pulmonale and suggested instead a component of volume depletion. The patient was rapidly volume resuscitated with prompt resolution of shock, indicating that his shock was not caused by pulmonary embolism.

How can hypovolemic shock be differentiated from septic shock at the bedside?

One of the more challenging distinctions to make with clinician ultrasonography is differentiating hypovolemic shock from septic shock, because both can have similar patterns on echocardiography before resuscitation (see **Table 2**). Patients with septic shock frequently have third space fluid losses and intravascular volume depletion, with decreased IVC size. For a patient with decreased IVC size and hyperkinetic left ventricle, other findings may be helpful to distinguish septic from hypovolemic shock (**Table 3**).

What if the ultrasonography examination in a shocked patient appears normal?

Bedside ultrasonography is often better at excluding diagnoses than ruling them in. It is common to encounter a patient in shock with a normal-appearing sonographic examination. This finding is most compatible with a diagnosis of distributive shock, usually caused by sepsis (see **Table 2**). Distributive shock may cause few abnormalities on echocardiography, often leaving it as a diagnosis of exclusion.

Can ultrasonography be used to guide sepsis resuscitation?

The primary utility of shock ultrasonography is the delineation of various shock states. However, clinician ultrasonography has also been shown to improve outcomes by

Table 3
Differentiation between septic shock and hypovolemic shock based on components of the traditional physical examination

Septic Shock	Hypovolemic Shock
Vasodilatation and a high–cardiac output state	Reduced cardiac output
Warm extremities Bounding pulse Low diastolic blood pressure Wide pulse pressure	Cold extremities Thready pulse Narrow pulse pressure
Patients typically manifest early with mental status changes, tachypnea, fever, and a toxic appearance	Mental status changes and a toxic appearance do not typically develop until the patient is severely shocked

guiding the use of volume administration, vasopressors, and inotropes during resuscitation.[12] Although controversial, patients with small and variable IVC are more likely to benefit from volume resuscitation than patients with large and invariant IVC. Similarly, patients with extremely hyperkinetic LVEF showing end-systolic obliteration are typically volume depleted and more likely to benefit from fluid resuscitation. The presence of an A-line pattern on lung ultrasonography excludes pulmonary edema and supports the safety of administering fluid, whereas the emergence of B lines bilaterally during resuscitation may signal evolving pulmonary edema.[13] During the course of sepsis resuscitation it is common for patients to develop sepsis-induced cardiomyopathy with a substantial reduction in LVEF; such patients may respond well to inotropes. If a septic patient is hypotensive despite adequate volume resuscitation and a normal or hyperkinetic LVEF, then reduced systemic vascular resistance is likely and may respond to treatment with a vasopressor such as norepinephrine. As always, ultrasonography findings should be integrated with other clinical parameters such as blood pressure and urine output when making treatment decisions. Following the recent publication of the PROCESS trial showing that it is safe to perform sepsis resuscitation without a central venous catheter, ultrasonography is likely to play a greater role in providing individualized noninvasive resuscitation.[14]

CLINICIAN SHOCK ULTRASONOGRAPHY: CLINICAL SCENARIO

What is the cause of shock in this patient?

A young woman with morbid obesity is found down at home following polysubstance intoxication. She is intubated and transferred to the intensive care unit, where she remains comatose. On hospital day #2, she becomes increasingly hypotensive and tachycardic. A bedside ultrasonography examination shows a dilated IVC, dilated RV, septal flattening, and increased LVEF.

How does this ultrasonography examination change assessment and management?

The presence of RV dilatation with septal flattening raised a question of pulmonary embolism. However, an alternative explanation for RV dilatation in this patient includes chronic pulmonary hypertension, caused by morbid obesity and associated obesity hypoventilation. Although this ultrasonography examination was not definitive, it alerted us to the possibility of pulmonary embolism and an emergent CT angiogram

was performed, which revealed a saddle pulmonary embolism. This finding was surprising given that the patient had only been hospitalized for 2 days. Without routine application of ultrasonography it is unlikely that the pulmonary embolism would have been detected in a timely fashion.

PERFORMANCE IMPROVEMENT

Like any clinical skill, bedside ultrasonography requires ongoing practice and review of the literature. We recommend that, whenever possible, before a patient is taken for a formal echocardiographic study, clinicians should perform their own studies, store the images if possible, and interpret their studies. Subsequently, these may be compared with the official study images and interpretation. In this manner, clinicians may obtain an objective and continuous source of feedback regarding the accuracy of their images and interpretation, and any areas for further improvement.

CLINICAL GUIDELINES

The American College of Chest Physicians has created a consensus statement regarding competence in critical care ultrasonography.[15,16] Clinician ultrasonography may be divided roughly into 3 components: image acquisition, interpretation of individual images, and integration of findings to recognize clinical syndromes. Specific goals are described for each of these components.

REFERENCES

1. Perera P, Lobo V, Williams SR, et al. Cardiac echocardiography. Crit Care Clin 2014;30:47–92.
2. Razi R, Estrada JR, Doll J, et al. Bedside hand-carried ultrasound by internal medicine residents versus traditional clinical assessment for the identification of systolic dysfunction in patients admitted with decompensated heart failure. J Am Soc Echocardiogr 2011;24(12):1319–24.
3. Joseph MX, Disney PS, DaCosta R, et al. Transthoracic echocardiography to identify or exclude cardiac cause of shock. Chest 2004;126(5):1592–7.
4. Perera P, Mailhot T, Riley D, et al. The RUSH exam: Rapid Ultrasound in SHock in the evaluation of the critically ill. Emerg Med Clin North Am 2010;28:29–56.
5. Rudski LG, Lai WW, Afilalo J, et al. Guidelines for the echocardiographic assessment of the right heart in adults: a report from the American Society of Echocardiography endorsed by the European Association of Echocardiography, a registered branch of the European Society of Cardiology, and the Canadian Society of Echocardiography. J Am Soc Echocardiogr 2010;23:685.
6. Saul T, Lewiss RE, Langsfeld A, et al. Inter-rater reliability of sonographic measurements of the inferior vena cava. J Emerg Med 2012;42:600–5.
7. Deol GR, Collett N, Ashby A, et al. Ultrasound accurately reflects the jugular venous examination but underestimates central venous pressure. Chest 2011; 139:95–100.
8. Lichtenstein DA, Meziere GA, Lagoueyte JF, et al. A-lines and B-lines: lung ultrasound as a bedside tool for predicting pulmonary artery occlusion pressure in the critically ill. Chest 2009;136:1014–20.
9. Volpicelli G, Lamorte A, Tullio M, et al. Point-of-care multiorgan ultrasonography for the evaluation of undifferentiated hypotension in the emergency department. Intensive Care Med 2013;39:1290–8.

10. Ding W, Shen Y, Yang J, et al. Diagnosis of pneumothorax by radiography and ultrasonography: a meta-analysis. Chest 2011;140:859–66.
11. Lichtenstein D. Lung ultrasound in the critically ill. Curr Opin Crit Care 2014;20:315–22.
12. Kanji HD, McCallum J, Sirounis D, et al. Limited echocardiography-guided therapy in subacute shock is associated with change in management and improved outcomes. J Crit Care 2014;29:700–5.
13. Lichtenstein D. FALLS-protocol: lung ultrasound in hemodynamic assessment of shock. Heart Lung Vessel 2013;5:142–7.
14. ProCESS Investigators, Yealy DM, Kellum JA, et al. A randomized trial of protocol-based care for early septic shock. N Engl J Med 2014;370:1683–93.
15. Sperandeo M, Rotondo A, Guglielmi G, et al. Transthoracic ultrasound in the assessment of pleural and pulmonary diseases: use and limitations. Radiol Med 2014;119(10):729–40.
16. Mayo PH, Beaulieu Y, Doelken P, et al. American College of Chest Physicians/La Societe de Reanimation de Langue Francaise statement on competence in critical care ultrasonography. Chest 2009;135:1050–60.