Paul G. Barash, MD
Giovanni Landoni, MD
Section Editors

Vascular Complications of Central Venous Catheter Placement: Evidence-Based Methods for Prevention and Treatment

Andrew Bowdle, MD, PhD

PRACTITIONERS, MANUFACTURERS, AND REGULATORY AGENCIES have long regarded central venous catheters (CVCs) as relatively dangerous, problem-prone devices. Recent attention has been focused primarily on reduction of infectious complications of CVCs. Application of strict aseptic precautions (the so-called "central-line bundle") when placing CVCs effectively has reduced the incidence of catheter-related infection,[1] and Medicare no longer reimburses for costs related to these infections.[2] However, mechanical complications of central venous cannulation remain a significant cause of morbidity and mortality. Data from the American Society of Anesthesiologists Closed Claims Project database have suggested that since 1990, the majority of mechanical complications associated with CVCs are vascular injuries,[3] and "accidental puncture or laceration" is a reportable National Quality Measures Patient Safety Indicator.[4] Fortunately, most vascular injuries from CVCs should be preventable

The purpose of this review is to examine evidence-based methods for preventing vascular complications of CVC placement. The diligent application of preventive measures can reduce the incidence of CVC-related vascular injuries to nearly zero. However, the evidence for treating vascular complications also will be examined, since CVC complications, even if infrequent, can be life-threatening. The review will be organized along anatomic lines, because the implications for arterial and venous injuries usually are different and the implications for intrathoracic vascular injuries usually are different from injuries outside of the chest.

ARTERIAL INJURY

Inadvertent arterial puncture with a small needle (18G and smaller) during CVC placement ranges from 4.2% to 9.3% in reported series.[5–8] A small needle puncture appears to be harmless in the vast majority of cases, and most of these small needle arterial punctures are recognized. However, failure to recognize the arterial puncture has resulted in subsequent placement of a large-bore catheter (>7 Fr) into an artery, ranging from 0.1% to 1.0% of attempted CVC placements in reported series.[9–13] Inadvertent arterial placement of a large-bore catheter may result in hemorrhage, pseudoaneurysm,[14] stroke, or death.[15,16]

AVOIDANCE OF ARTERIAL INJURY

The traditional method for avoiding arterial placement is to observe the color and pulsatility of blood coming from the needle hub before placement of the guidewire. However, this approach has been shown to be unreliable.[5–7,17] Measurement of blood gases to assess the degree of oxygenation has been used as a more reliable alternative to color; however, most practitioners would regard this as impractical due to the delay required to make the measurement. Ultrasound guidance and pressure monitoring have been suggested as practical and more reliable alternatives to color and pulsatility for distinguishing vein from artery.

ULTRASOUND GUIDANCE

The availability of relatively inexpensive, portable ultrasound equipment led to the application of 2D ultrasound imaging to guide CVC placement. Ultrasound imaging allows the presence of the internal jugular vein (IJV) to be confirmed, its patency to be demonstrated, and its anatomical relationship to the carotid artery to be defined. Real-time (or "dynamic") ultrasound can guide needle placement into the vein and confirm the presence of a wire in the vein. Troianos et al first reported the use of ultrasound-guided central vascular access in the anesthesia literature in 1991.[17] Their prospective, randomized study of ultrasound guidance versus the traditional landmark method found a higher overall success rate, a higher success rate on the first attempt, and a reduced rate of arterial puncture with ultrasound guidance. Numerous studies of ultrasound guidance and meta-analyses have appeared subsequently. Meta-analyses of ultrasound guidance concluded that ultrasound guidance was superior to the landmark method for overall success rate, a higher success rate on the first attempt, and reduced complications from arterial puncture for the IJV approach.[18,19] The advantage of ultrasound guidance for the subclavian approach is diminished, because the subclavian vein is less easily imaged

From the Department of Anesthesiology, University of Washington, Seattle, WA.

Address reprint requests to Andrew Bowdle MD, PhD, Department of Anesthesiology, Mail Stop 356540, Room AA177C, University of Washington, Seattle, WA 98195. E-mail: bowdle@u.washington.edu

1053-0770/2605-0031$36.00/0

http://dx.doi.org/10.1053/j.jvca.2013.02.027

Key words: central venous catheter, invasive monitoring, complications, catheterization, central venous, subclavian vein, internal jugular vein

with ultrasound due to interference from the clavicle; a study of 821 patients compared ultrasound guidance with standard insertion procedures for cannulation of the subclavian vein and concluded that ultrasound had no effect on the rate of complications.[20] A review commissioned by the Agency for Healthcare Research and Quality (AHRQ) strongly advocated the use of ultrasound guidance during CVC placement.[21] In the United Kingdom, the National Institute of Clinical Excellence recommended routine use of ultrasound for central venous catheterization.[22] Other published guidelines recommended the use of ultrasound during CVC placement.[23–26]

Despite the abundance of data in favor of the use of ultrasound guidance, the available data suggest that adoption into practice has been limited. A survey of Society of Cardiovascular Anesthesiologists members published in 2007 revealed that only 15% always or almost always used ultrasound.[27] Interestingly, most of those surveyed had experienced vascular complications during CVC, including carotid artery puncture (75%), carotid injury (3%), stroke (1%), and hemothorax (4%). The use of ultrasound guidance may have increased since 2007. A shortage of suitable ultrasound equipment is sometimes a reason for not using ultrasound guidance. A study in the UK found that 86% of anesthetic departments had ultrasound equipment for central line placement;[28] however, Bailey et al found that 33% of anesthesiologists in their survey of members of the Society of Cardiovascular Anesthesiologists never or almost never had ultrasound equipment available.[27]

Although the value of ultrasound guidance is well established, it is important to recognize that arterial puncture is reduced in frequency, but not entirely eliminated. Troianos et al found that ultrasound guidance reduced the incidence of arterial puncture from 8.4% to 1.4% during attempted IJV cannulation.[17] By contrast, Hameeteman et al reported a much higher incidence of arterial puncture with ultrasound guidance—7.8% during IJV CVC placement by surgical trainees.[8]

There are numerous reports of inadvertent arterial placement of large-bore catheters despite the use of ultrasound guidance.[29–33] There are a number of reasons that this can occur. First, the needle tip may not be seen in the ultrasound beam. Because of the tomographic nature of ultrasound, distinguishing the tip from the shaft of the needle requires multiple ultrasound views and a substantial degree of skill on the part of the sonographer. The shaft of the needle may be imaged in the vein while the tip of the needle is located in the adjacent artery, unsuspected by the operator. Second, the needle may be in the vein and properly imaged with ultrasound, but the needle may move into the artery during placement of the guidewire, at which point most operators are not using live ultrasound. Because of the possible difficulty with reliably imaging the tip of the needle in the vein, imaging the guidewire in the vein with ultrasound before placing a large-bore catheter has been recommended. Although imaging the guidewire in the vein is a potentially useful maneuver to confirm proper placement, it is not infallible, because the guidewire can pass through the vein (due to a through-and-through puncture with the needle) and into the adjacent artery. This may not be appreciated with ultrasound, particularly when the guidewire passes through the IJV and into the adjacent subclavian artery, which lies under the clavicle and may not be seen well with ultrasound (Fig 1A) The right subclavian artery is in close proximity when the right IJV is approached low in the neck. Kulvatunyou et al reviewed a collection of cases of injury to the right subclavian artery during attempted right IJV cannulation.[34] An example of inadvertent cannulation of the right subclavian artery is shown in Fig 1B.

A case series reported by Blaivas[30] presented 6 inadvertent arterial cannulations that occurred despite the use of dynamic ultrasound guidance. He noted that "the casual reviewer may assume that serious complications no longer arise when ultrasound is used" and then proceeded to demonstrate that this assumption was not correct. The physicians who either personally placed or supervised residents placing the CVC in each of the 6 cases were credentialed by their hospital in emergency ultrasound based on American College of Emergency Physicians ultrasound criteria. All residents received a 2-day introductory ultrasound course, which included 3 hours of didactic and hands-on education in ultrasound-guided vascular access.

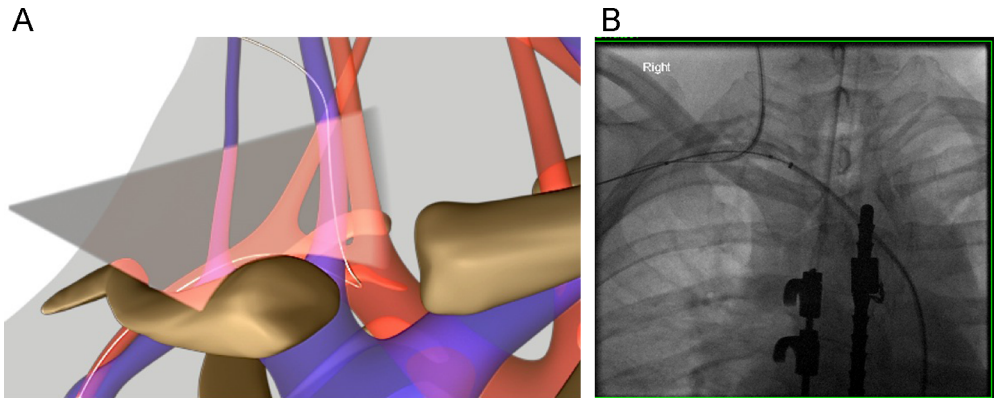

Fig 1. (A) In the drawing, a guidewire is seen to enter the internal jugular vein, exit the vein, and then enter the adjacent subclavian artery. The guidewire then travels distally in the subclavian artery. Because the point of exit from the vein and entry into the artery is beneath the clavicle, the ultrasound image of the wire in the internal jugular vein, indicated by the triangular shaded area representing the ultrasound beam, may appear normal. This mechanism of inadvertent arterial cannulation is not rare because of the close relationship of the right subclavian to the right internal jugular vein.[34] (B) The x-ray shows a CVC that has been inadvertently placed into the right subclavian artery during attempted CVC placement from the right internal jugular vein. The interventional radiologist has advanced a wire and catheter from the femoral artery that will be used for endovascular treatment of the injured subclavian artery. (Color version of figure is available online)

Table 1. Video Analysis of Six Accidental Arterial Cannulations with Dynamic Ultrasound Guidance[30]

Age	Mechanism of Injury	Outcome
67	Needle went through IJV into Carotid artery	Patient died
75	Needle went though femoral vein into femoral artery	Vascular surgery for arteriovenous fistula
48	Needle went though IJV and entered carotid artery underneath the IJV	Surgery for tear and focal dissection of carotid artery
67	Guidewire traveled through IJV and its posterior wall and into carotid artery	Hematoma with respiratory distress requiring emergent intubation
69	Needle penetrated the carotid artery which was very close to the IJV	Emergency carotid artery repair; patient died of complications
14	Needle penetrated rear wall of IJV and entered carotid artery	Central catheter removed and bleeding eventually stopped

Abbreviations: IJ, internal jugular vein.

Table 1 summarizes each of the 6 cases, including an analysis of the error based on a video review of the ultrasound-guided arterial cannulation. The mechanism of injury in 5 of the 6 cases involved passage of the needle through the vein, out its posterior wall, and into the artery.

While ultrasound guidance clearly is useful during CVC insertion, its use has not eliminated the risk of arterial cannulation, especially when the insertion site is the subclavian vein. Moreover, the adoption of ultrasound has been somewhat limited, despite the existence of guidelines recommending routine use.

PRESSURE MEASUREMENT

Measurement of pressure in the needle is a highly reliable method for distinguishing artery from vein,[5-7] and can be used alone or in combination with ultrasound guidance to prevent inadvertent arterial cannulation. Ezaru et al[5] and Jobes et al[6] found that 0.8% of CVC attempts resulted in arterial punctures that were not recognized by color or pulsatility, but that all arterial punctures were recognized by measuring pressure (Table 2). Traditional methods for pressure measurement include column manometry (sterile tubing attached to the needle and allowed to backfill with blood) (Fig 2) or the use of a pressure transducer, connected to the hub of the needle by a length of sterile pressure tubing with the results displayed on a monitor (Fig 3).[35]

More than 25 years ago Jobes et al performed a retrospective study of 1,021 attempts at IJV access in which there were 43 arterial punctures.[6] Five of the 43 arterial punctures were unrecognized, resulting in the placement of 8-Fr introducer sheaths into an artery (0.5% arterial cannulation rate), resulting in one fatality from hemothorax. Subsequently, these investigators performed a prospective trial of 1,284 attempts at IJV access in which they measured a pressure waveform from the vessel before inserting the guidewire.[6] Before measuring the pressure waveform, a clinical assessment was made as to whether the 20G catheter was in an artery or vein, based on the usual criteria of color and pulsatility. There were 51 arterial punctures, 10 of which were identified incorrectly as being venous based on color and pulsatility, but were determined to be arterial from the pressure waveform. Thus, 10 inadvertent arterial cannulations (0.8%) were avoided by measuring the pressure waveform.

In 1997, Oliver et al reported the results of placing 1,172 CVCs into the internal jugular, subclavian, or femoral veins

Table 2. Arterial Cannulations Prevented by Pressure Measurement

Author	Year	Number CVCs	Arterial Cannulations	Arterial Cannulations Prevented by Pressure Measurement
Jobes[6]	1983	1284	0	10 (0.8%)
Ezaru[5]	2009	511	0	4 (0.8%)

Abbreviations: CVC, central venous catheter.

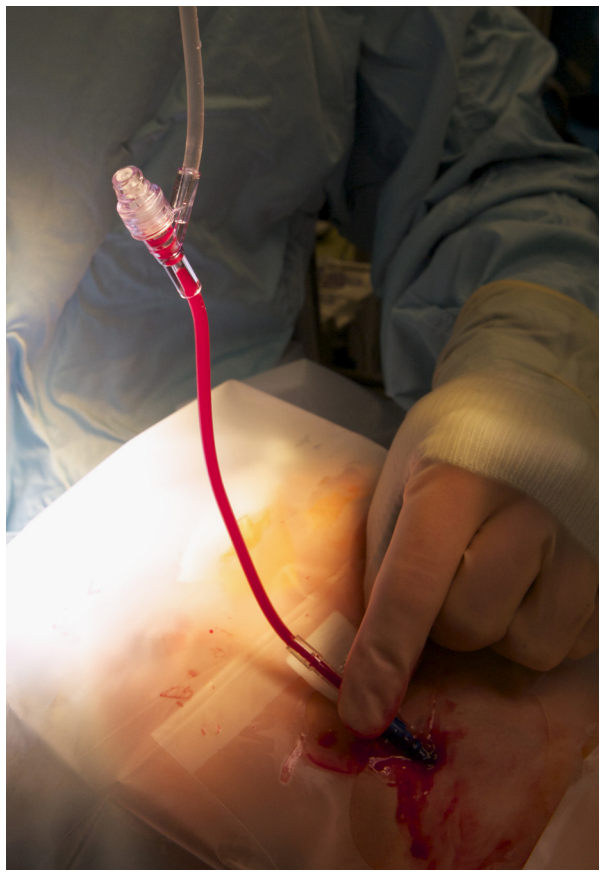

Fig 2. The pressure measurement method of tube manometry is illustrated. A length of tubing is connected to the hub of the needle or short plastic catheter , and the tubing is held below the level of the vein to fill with blood, or a syringe can be used to fill the tubing. The tubing then is held vertically above the patient. The blood-air interface will settle at a level where the hydrostatic pressure in the tubing is equal to the intravascular pressure. If the needle or short plastic catheter is in an artery (and the blood pressure is normal), the blood will rise out the top of the tubing and over flow. (Color version of figure is available online)

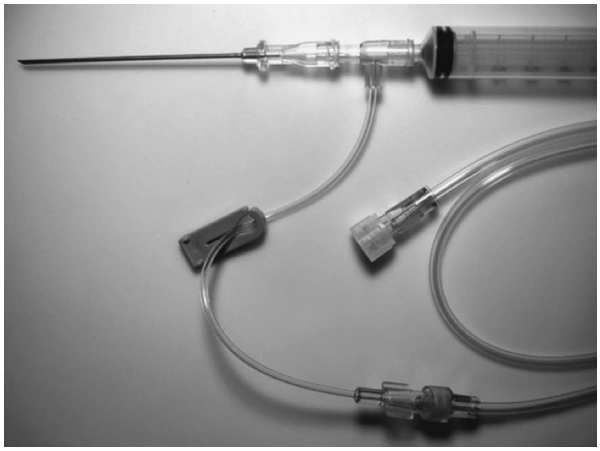

Fig 3. The author has used this setup for pressure measurement since the mid 1980s. The t-shaped plastic adapter and a length of sterile pressure tubing are added to a standard CVC kit. The t-shaped adapter is placed between the needle and the syringe, and the sterile pressure tubing is handed off to a nonsterile assistant who connects it to a standard pressure transducer. When the needle enters the blood vessel the pressure waveform can be read immediately from the physiologic monitor without the need to disconnect anything from or connect anything to the hub of the needle. After verifying a venous waveform, the syringe or the t-shaped adapter is removed and the guidewire is inserted. The pressure cannot be measured during guidewire placement because the system is open to the atmosphere.

using pressure transduction through the introducer needle to confirm venous access before guidewire insertion.[7] The incidence of arterial puncture was 9.3% (defined as entry of the introducer needle into an artery), but pressure transduction correctly identified all the arterial punctures and there were no cases of inadvertent arterial cannulation.

In 2009, Ezaru et al published a retrospective analysis of 9,348 CVC placements over a 15-year period in a single institution, requiring mandatory use of tube manometry to verify venous access.[5] There were no cases of arterial cannulation. During the final year of the study, 511 catheters were placed. Arterial puncture (defined as placement of an 18-gauge introducer needle or catheter into an artery) occurred in 28 patients (5%). Arterial puncture was recognized correctly from color and pulsatility in 24 cases, without manometry, but in 4 cases (0.8%), the arterial placement was only recognized with manometry.

The three articles summarized above (Jobes et al,[6] Oliver et al,[7] and Ezaru et al[5]), presenting data from 11,804 patients, showed that measuring the pressure could prevent inadvertent arterial cannulation. Importantly, both Ezaru et al[5] and Jobes et al[6] found that without pressure monitoring, reliance upon the blood color and pulsatility alone would have resulted in an arterial cannulation rate of 0.8%.

The American Society of Anesthesiologist's guideline for CVC placement[23] states that color and pulsatility are not reliable for distinguishing vein from artery. Nevertheless, anecdotal reports suggest that pressure measurement has not been adopted widely. In part, this may be due to a lack of awareness of the problem of inadvertent arterial cannulation, and perhaps there is a perception that ultrasound has eliminated the risk. However, as discussed previously, inadvertent arterial cannulation has not been eliminated by ultrasound.

Pressure measurement may be viewed as cumbersome by some practitioners. For example, an editorial regarding tube-based manometry stated, "In manipulating the 18-gauge cannula to affix the extension tubing and then aspirating or manipulating the cannula tubing to obtain a sufficient column of blood, one could envision many other mishaps: Air embolization, dislodgement of the cannula, infection, and violation of the sterile field are very real possibilities."[36]

TECHNIQUES FOR PRESSURE MEASUREMENT

There are 3 common methods of measuring pressure during CVC placement: Manometry, connection to a conventional pressure transducer via sterile tubing, and the use of a compact, sterile, single-use pressure transducer with an integral digital display and guidewire port (Compass, Mirador Biomedical, Seattle, Washington) (Fig 4).

Manometry is accomplished by connecting a length of sterile tubing to the hub of the needle or catheter, allowing it to fill with blood, then holding it vertically and allowing the blood level to equilibrate with venous pressure (Fig 2). The venous pressure will be apparent in the height of the fluid column. If the needle or catheter is arterial, the fluid column would be expected to continue to rise to the top of the vertically held tubing and overflow. The advantage of manometry is that it is inexpensive and can be performed by the operator without an assistant and without the need for a physiologic monitor. Disadvantages include the need to open the needle or catheter hub to connect the tubing and the possibility of dislodging the needle or catheter from the vein in the process of making the measurement.

Pressure measurement with a conventional transducer requires that a length of sterile pressure tubing be connected to a transducer outside of the sterile field. The pressure then is measured using a physiologic monitor. The connection of the sterile tubing to the needle or catheter hub can be made using a variety of methods. The simplest method is to directly connect the male connector end of the sterile tubing to the needle or

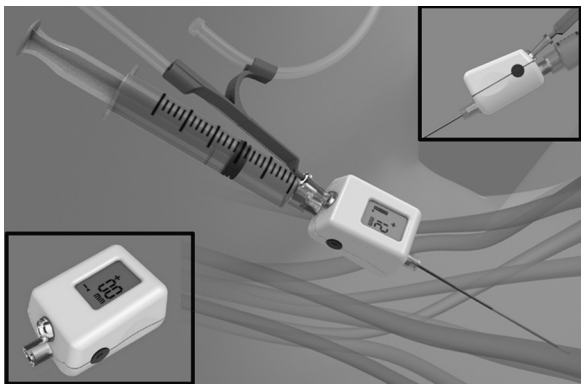

Fig 4. The Compass is a compact, sterile, single-use pressure transducer with an integral digital display and sealed guidewire port. The advantages of this device include: (1) The pressure can be measured without disconnecting and reconnecting anything from the hub of the needle and (2) the sealed guidewire port allows pressure to be measured during guidewire placement, verifying that the needle has not moved into the artery.[37]

catheter hub. The disadvantage of this method is that the needle or catheter hub has to be opened to make the connection. A stopcock or T-shaped adapter can be interposed between the needle or catheter hub and the syringe, allowing connection of the transducer tubing before insertion of the needle into the vein; in this case there is no need to open the hub of the needle or catheter to measure the pressure (Fig 3). If an Arrow Raulerson syringe (Teleflex Incorporated) is being used during CVC placement, a purpose-made blunt needle connected to the transducer tubing can be inserted through the hemostasis valve in the plunger of the Raulerson syringe; this method also avoids the need to open the hub of the needle or catheter to measure the pressure.

A compact, sterile, single-use transducer with an integral digital display and sealed guidewire port is available (Compass, Mirador Biomedical) (Fig 4). This device self calibrates to atmospheric pressure when activated. The mean pressure and an analog representation of the pressure waveform are displayed on a small LCD screen. After aspiration of blood from the vein with a syringe, the venous pressure and waveform are verified and a guidewire is inserted into the dedicated, sealed guidewire port. After guidewire placement, a venous pressure and waveform are verified again, providing protection against unrecognized insertion of the needle into the adjacent artery during guidewire placement. If the needle is moved accidentally into an artery during guidewire placement, an arterial pressure and waveform will appear. Advantages of the Compass include performing the entire procedure without opening the hub of the needle, not requiring an assistant or physiologic monitor, and being able to measure the pressure during guidewire placement. A multicenter utility study of the Compass found that the device functioned properly and accurately detected 5 arterial needle placements during 298 CVC placements; all 5 of the arterial needle placements occurred with ultrasound guidance.[37] A cost-effectiveness analysis suggested that routine use of the Compass for CVC placement likely would be cost effective, saving $116 per CVC during placement of 1000 CVCs.[37]

SHORT PLASTIC CATHETER VERSUS METAL NEEDLE

The first step in placing a CVC is to access the vein with a small needle. This can be done with either a bare metal needle or a short plastic catheter-over-needle (ie, intravenous catheter). Although this choice largely is a matter of personal style, there are some important safety considerations that should be kept in mind. When a metal needle is used, there is the possibility that the needle can be moved inadvertently into an adjacent artery after identifying the tip of the needle in the vein with ultrasound and/or pressure measurement. This may be unrecognized by the operator and can result in accidental arterial cannulation. One of the major advantages of the sealed guidewire port of the Compass transducer is that the pressure can be measured during guidewire placement; if the needle accidentally enters the artery during guidewire placement, an arterial pressure will appear on the Compass LCD screen.

If the short plastic catheter-over-needle is used, the plastic catheter is unlikely to move from the vein after placement. Therefore, if a venous pressure is measured from the hub of the plastic catheter, there is little chance that the catheter will enter the artery during guidewire placement. This is a major advantage to the use of the plastic catheter-over-needle method. However, the plastic catheter-over-needle method has the disadvantage that the hub of the catheter has to be opened after placement in the vein to connect tubing for pressure measurement or to insert a guidewire.

ULTRASOUND GUIDANCE AND PRESSURE MEASUREMENT ARE COMPLEMENTARY

Ultrasound guidance sometimes is compared with pressure measurement with the suggestion that pressure measurement is unnecessary if ultrasound guidance is used or, conversely, that ultrasound guidance is unnecessary if pressure measurement is used. However, ultrasound guidance and pressure measurement are best seen as complementary rather than as alternative methods. As explained fully elsewhere in this review, ultrasound guidance reduces the frequency of arterial puncture but does not reliably prevent inadvertent arterial cannulation. Ultrasound guidance should be thought of as a way to make initial entry into the vein faster and more reliable, with fewer and more accurately directed needle punctures, by showing the operator the exact location of the vein. Pressure measurement should be thought of as the most reliable method of avoiding inadvertent arterial cannulation. These techniques are complementary, and logic suggests that they should be used together to have the lowest possible incidence of mechanical complications during CVC placement. Although there are no clinical trials directly comparing ultrasound guidance with pressure measurement or the combination of ultrasound guidance and pressure monitoring with either method by itself, the literature describing the performance of ultrasound guidance and pressure monitoring individually is clear enough that further clinical trials probably are unnecessary and unlikely to be carried out due to safety concerns.

FLUOROSCOPY AND ECHOCARDIOGRAPHY

Fluoroscopy and echocardiography can be used to identify the anatomic location of guidewires. Interestingly, the use of fluoroscopy for this purpose is standard in interventional radiology, cardiology, and for surgically implanted CVCs, but is seldom used in anesthesiology, critical care medicine, or emergency medicine. Fluoroscopy has the advantage of imaging the entire course of a guidewire, not just at the vascular entry point. However, it is important to recognize that inferring whether a guidewire is in an artery or a vein with fluoroscopy is indirect and based on the slightly different location and course of adjacent arteries and veins. Fig 5 shows a case in which a guidewire that was thought to be in the superior vena cava based on the fluoroscopic appearance actually was in the ascending aorta.

Fluoroscopy also offers the possibility of observing the course of dilators and catheters as they are advanced into the venous system, in real time. This can help to prevent injuries to veins (see “Venous Injury” and Figs 8–10 below).

Transesophageal echocardiography can be utilized to identify a wire in the vena cava or right atrium (Fig 6). If the transesophageal echocardiography probe has been inserted before CVC placement, the guidewire may be identified in the superior vena cava or right atrium as final confirmation of

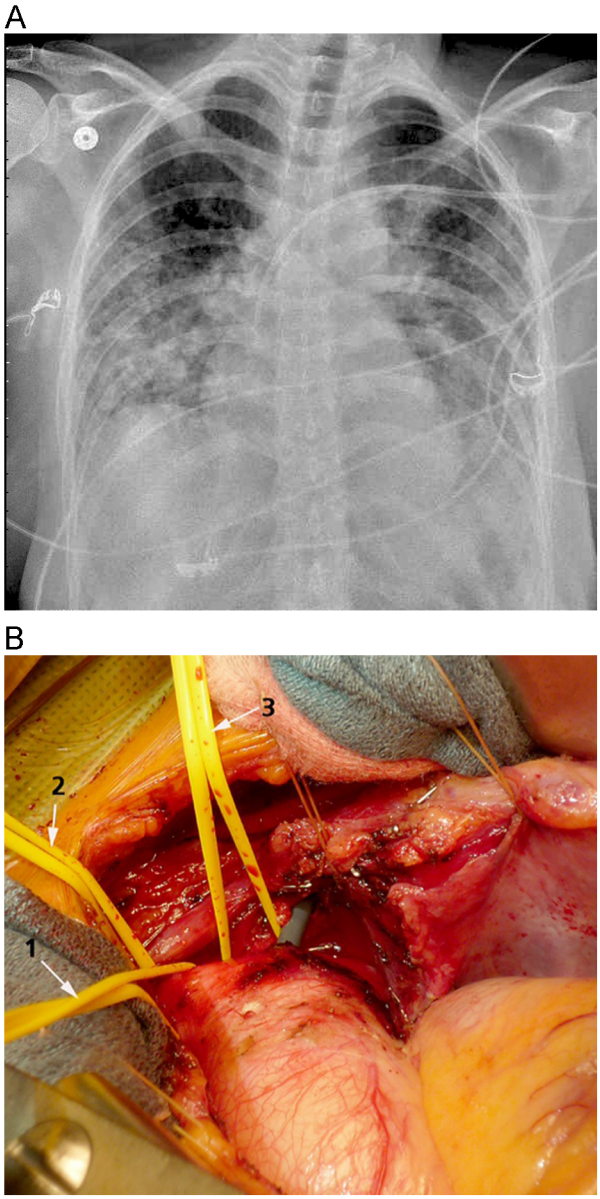

Fig 5. (A) A woman underwent attempted port placement for chemotherapy. The surgeon inserted a guidewire and then a long catheter into what was believed to be the left subclavian vein. The locations of the guidewire and catheter were observed with fluoroscopy, as shown in the intraoperative x-ray. After placement of the catheter, the surgeon became suspicious of possible arterial placement. The procedure was abandoned, and the patient was transferred to a hospital with cardiac surgery capability. Additional imaging studies showed that the catheter had perforated the ascending aorta. (B) A median sternotomy was performed, the catheter was removed, and the aorta was repaired directly. The numbers refer to blood vessels that have been controlled with vessel loops: (1) Right common carotid artery, (2) left innominate vein, (3) left common carotid artery. This complication would almost certainly have been prevented had pressure in the needle hub been measured before guidewire placement. This case also illustrated that fluoroscopy, while useful, is not infallible for confirming venous placement of the guidewire. (Color version of figure is available online)

proper guidewire placement before inserting a large-bore catheter or introducer sheath.

TREATMENT OF ARTERIAL INJURY

While diligent use of ultrasound guidance and pressure monitoring should reduce the incidence of inadvertent arterial placement of CVCs to nearly zero, it is important to know what to do in the event that such a complication should occur. After inadvertent placement of a large-bore catheter into an artery, the possible remedies are: (1) Simply remove the catheter and apply pressure ("pull and pressure"), (2) direct surgical repair, and (3) endovascular repair.

The "pull-and-pressure" approach is reasonable in the case of femoral artery cannulation, and, of course, this is often done when the femoral artery has been cannulated deliberately for coronary angiography, placement of an intraaortic balloon pump, or other purposes. Alternatively, there are a variety of vascular closure devices available. Whether direct pressure or a vascular closure device is used after deliberate femoral arterial cannulation, complications may result, including bleeding, hematoma, thrombosis, pseudoaneurysm, and arteriovenous fistula. Interestingly, the use of ultrasound guidance has been shown to decrease complications from femoral artery cannulation for percutaneous cardiac interventions.[38]

The "pull-and-pressure" approach is not applied so easily to the carotid or subclavian arteries, because it is difficult or impossible to effectively compress these vessels. Nevertheless, the "pull-and-pressure" approach has been tried. Shah et al systematically examined the difference between the "pull-and-pressure" technique and open surgical treatment for inadvertent cannulation of the carotid or subclavian artery.[15] They performed a retrospective review of 14 years' experience in a

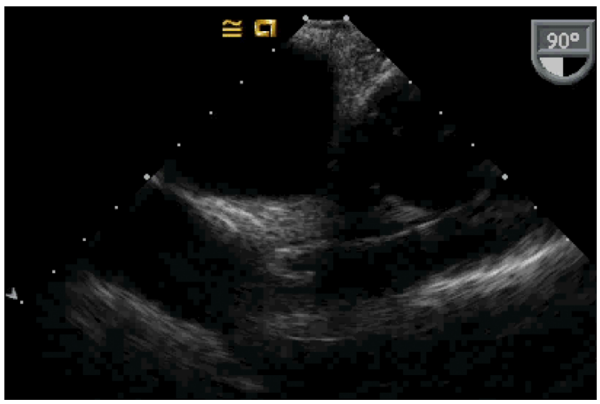

Fig 6. A guidewire with a typical J-tip is shown in the superior vena cava in this TEE image. The tip of the guidewire is located at approximately the atrial-caval junction. This method has the dual purpose of confirming that the guidewire has been placed in a vein and not an artery and that the guidewire has proceeded down the vena cava, rather than the subclavian or internal jugular vein. If TEE is being used for intraoperative monitoring or diagnosis and can be placed before CVC placement, this use for confirming guidewire position is attractive. However, this method generally will require 2 operators, one to operate the TEE probe and one to insert the CVC.

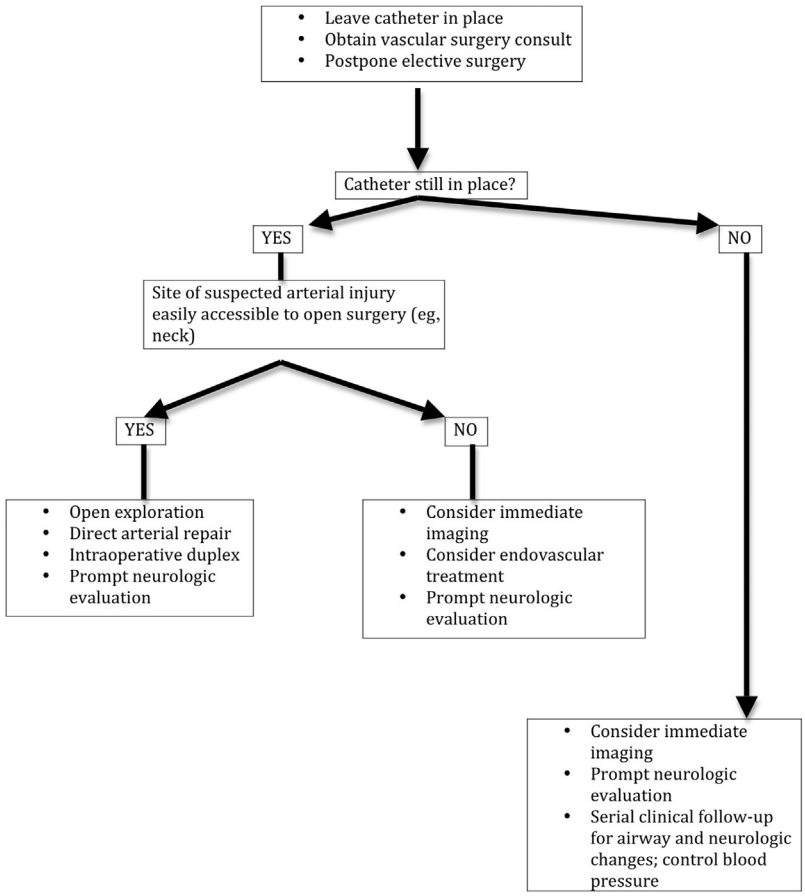

Fig 7. Guilbert et al have proposed this algorithm for the treatment of inadvertent arterial placement of large-bore catheters based on their study of cases within their own hospitals and also previous reported series. Their analysis suggested that the "pull-and-pressure" approach had a very high rate of morbidity and mortality, whereas direct surgical repair of carotid artery injury or endovascular repair of intrathoracic artery injury had a very low rate of morbidity and mortality.[16]

single center managing inadvertent arterial cannulation during attempted IJV cannulation. They identified 11 patients with inadvertent cannulation of either the carotid or subclavian artery with either 8.5Fr introducer sheaths or triple lumen catheters. In 2 patients, the sheath was pulled and pressure applied; one suffered a stroke and the other developed a pseudoaneurysm that later was treated surgically. Subsequently, 9 patients had the catheter removed surgically; none of those patients had additional complications. There are numerous interesting details included in this report. In 3 patients, the misplaced catheter was not identified on chest x-ray, and was recognized only when infusion of fluids into the catheters with peristaltic pumps resulted in neurologic symptoms. In 3 of the cases, the catheter passed through both sides of the IJV before entering the artery. Shah et al also reviewed 4 previous studies of the incidence of inadvertent arterial cannulation published between 1979 and 1995.[9,10,13,39] Out of a combined total of 11,870 attempted IJV cannulations, there were 20 inadvertent arterial cannulations, an incidence of 0.17%. The "pull-and-pressure" technique was applied in 19 of these 20 patients. Six of these patients suffered complications, and 2 died. Based on the experience in their center, and their review of the literature, Shah et al recommended direct surgical repair as the treatment of choice for inadvertent arterial cannulation of the carotid or subclavian artery with large bore (>7Fr) catheters.

In 2008, Guilbert et al confirmed the findings of Shah et al.[16] They found that morbidity and mortality from the "pull-and-pressure" approach was unacceptably high, while a direct operative or endovascular repair yields clearly superior results. They identified cases of carotid or subclavian injury associated with central venous catheterization from 3 large centers in Montreal (Table 3), and, in addition, gathered cases from the literature published between 1980 and 2006.

Their own case series contained 13 patients. Five were treated with "pull and pressure," and the remaining 8 patients were treated with either open repair (6) or endovascular repair (2). All of the patients treated with "pull and pressure" had major complications, including the death of one patient (Table 3); whereas the patients treated with open or endovascular repair did not suffer additional complications. During their literature review of 30 additional patients, they found that the "pull-and-pressure" method was associated with a high incidence of serious complications (47%), including death, whereas open surgical or endovascular repair was not

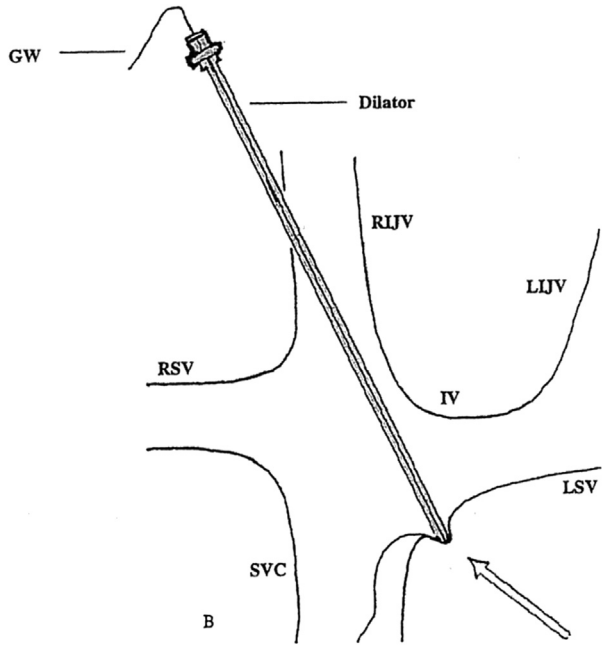

Fig 8. Oropello et al created this figure to illustrate one possible mechanism of venous injury during placement of a CVC from the internal jugular vein. The wire has been "trapped" against the wall of the vein, and a stiff dilator of an introducer sheath has perforated the wall of the vein at the site where the wire was trapped. The cases shown in Figs 9 and 10 also illustrate this mechanism of injury. One possible method for avoiding this complication is to demonstrate that the wire can be moved back and forth a few centimeters during insertion of the CVC, suggesting that the wire is not trapped. Probably a more reliable method is to observe the insertion of the CVC with live fluoroscopy, observing the course of the wire, dilator and catheter. However, fluoroscopy seldom is used for CVC placement in anesthesiology, critical care, or emergency medicine practice.

associated with any additional morbidity or mortality. In a fascinating prologue to their manuscript, Guilbert et al presented their data at the 2007 meeting of the Canadian Society of Vascular Surgery. A pre-test of the attendees revealed that respondents managed arterial injury from attempted central venous cannulation 1-5 times per year and that two-thirds would simply pull the catheter and apply pressure. However, when these vascular surgeons were shown the data from the study by Guilbert et al, most of them changed their preferred management to open surgical or endovascular repair when queried on a post-test.

Based on their own experience and review of the literature, Guilbert et al proposed the management algorithm shown in Figure 7.[16] In this algorithm, the catheter should be left in place at first. If the site is easily accessible surgically, such as the carotid artery, direct exploration, removal of the catheter, and repair are recommended. If the site is not easily accessible surgically, such as the subclavian artery, endovascular repair is recommended. There are now numerous descriptions of endovascular repairs of catheter-related injuries using a variety of stents and closure devices.[11,12,40–45]

Several of the specific findings of the Guilbert et al study are worth noting:

1. Arterial cannulation can occur despite the use of ultrasound guidance.
2. The low IJV approach can injure the subclavian or innominate arteries or even the aorta. Arterial injury below the sternoclavicular joint cannot be repaired through a

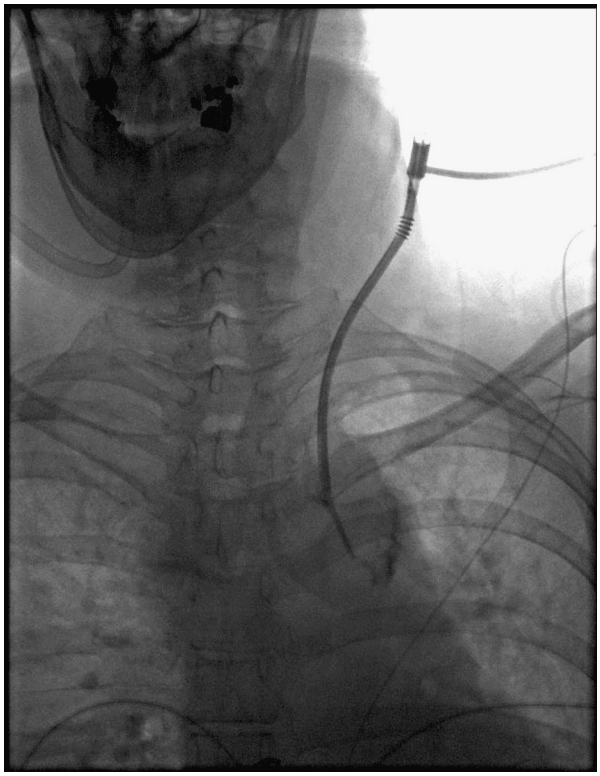

Fig 9. This intraoperative fluoroscopic image shows an introducer sheath that was placed into the left internal jugular vein. A CVC was placed through the introducer sheath. After placement, blood could not be aspirated from the CVC. Contrast was injected to further delineate the location of the tip of the sheath. The contrast appeared to extravasate into the mediastinum, but not the pleural space. Based on this finding, the decision was made by the interventional radiologist to remove the CVC, with a plan for percutaneous intervention should significant bleeding occur. Bleeding was self-limited and did not require further treatment. It is important to ascertain that the tip of the CVC is not in the pleural space. Removing the catheter under that circumstance could result in massive pleural hemorrhage. The mechanism of this injury is most likely the one illustrated in Fig 8, in which the tip of the CVC is trapped against the vein. This problem probably is more likely to occur with the left side internal jugular vein approach, compared to the right internal jugular vein approach, because the inferior wall of the left innominate vein is at a relatively acute angle to the path of the left internal jugular vein. Thus, the guidewire can make a relatively acute right-hand bend as it enters the innominate vein from the left internal jugular vein, and the guidewire can be trapped at that point when the introducer sheath, dilator, or CVC is advanced. As with the case illustrated in Fig 8, fluoroscopy is probably the most useful tool for avoiding this problem, as the course of the guidewire, dilator, or CVC catheter can be observed in real time as they are advanced. The author strongly prefers to have fluoroscopy available when placing a CVC from the left internal jugular vein, although clearly the use of fluoroscopy is not the standard of care for CVC placement in anesthesiology, critical care, or emergency medicine practice.

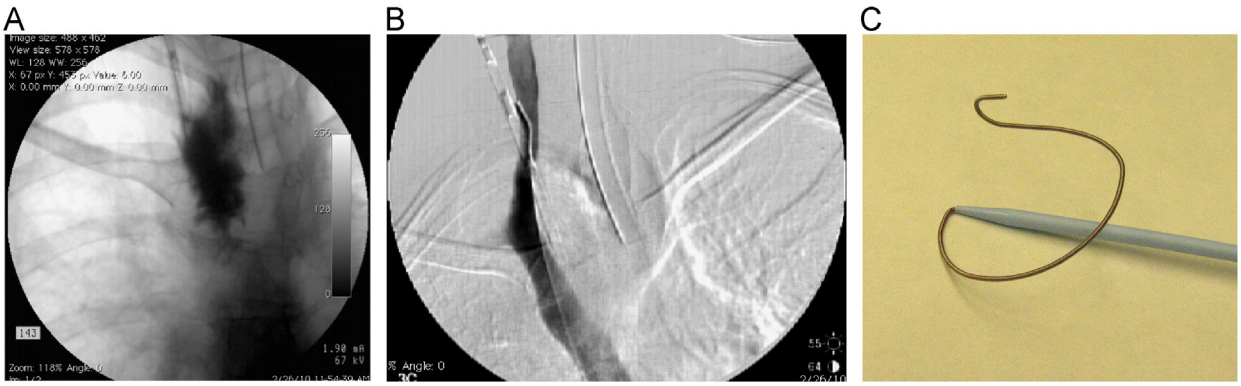

Fig 10. (A) After placement of an introducer sheath in the right internal jugular vein with ultrasound guidance and pressure measurement, no blood could be aspirated from the sheath. A small amount of x-ray contrast was injected into the sheath, and fluoroscopy showed extravascular dye in the lower neck and upper mediastinum. (B) An interventional radiologist then made the venogram shown in the figure, revealing that the sheath entered the internal jugular vein and then exited the internal jugular vein above the clavicle. The sheath was withdrawn, and an intravascular balloon was inflated in the internal jugular vein for a short period of time to limit bleeding. After balloon deflation, a repeat venogram showed that the entry and exit points had sealed. The mechanism of this injury would appear to be similar to that shown in Fig 8, in which a dilator perforates the vein after trapping the guidewire against the wall of the vein. (C) The dilator and guidewire from the case illustrated in A and B are shown. Note the deformity of the wire. (Color version of figure is available online.)

cervical approach. Clinical suspicion of an intrathoracic injury should prompt imaging to locate the site of injury and plan surgical or endovascular treatment.

3. Prolonged arterial cannulation can result in thrombus formation and stroke.
4. A normal carotid duplex examination after removal of a catheter from the carotid artery does not rule out the possibility of a stroke. Because of this, postponing elective surgery has been recommended to avoid unrecognized stroke in an anesthetized patient.
5. False aneurysms or arteriovenous fistulae can occur late after the pull-and-pressure technique, so close follow-up is needed.

VENOUS INJURY

Although the greatest emphasis in preventing vascular injury during CVC placement concerns avoiding inadvertent cannulation of arteries, injuries to intrathoracic veins also are potentially life threatening complications. This problem has not been studied systematically and most of the understanding is anecdotal. Probably the most common injury is a through-and-through injury to an intrathoracic vein (superior vena cava, innominate, subclavian). Hypothetically, a guidewire alone might perforate a vein; however, there is very little evidence that this actually happens with flexible spring guidewires. The most likely mechanism of injury is that a guidewire becomes trapped against the wall of a vein by a stiff dilator, sheath, or catheter that is being advanced over the guidewire, and the vein is perforated or torn, as shown in Figures 8-10.[46] This injury can result in catastrophic hemorrhage, especially if the injury to the vein communicates with the pleural space, which can fill rapidly with blood.

Obviously, conventional ultrasound guidance or pressure measurement will not prevent this complication. Probably the best preventive measure is to use fluoroscopy to observe the course of the guidewire and to observe the CVC as it is advanced over the guidewire to be sure it is following a proper anatomic pathway. Other preventive measures that may be useful include moving the guidewire back and forth slightly during insertion of the CVC to be sure that the wire is not trapped against the vein and visualizing the guidewire in the superior vena cava or right atrium with TEE before advancing the CVC (Fig 6). Difficulty inserting a guidewire should suggest immediately that the guidewire has taken an abnormal course into a branch vessel or has curled back on itself, which may increase the risk of injuring the vein while inserting the CVC. The use of fluoroscopy to determine the cause of difficulty advancing the guidewire should be considered strongly under these circumstances.

Hemothorax

Perforations of arteries or veins inside the chest can result in hemothorax if the perforation communicates with the pleural

Table 3. "Pull-and-Pressure" Versus Surgical or Endovascular Repair of Inadvertent Arterial Cannulation[16]

Management	Complications
Catheter removal and compression	Patient had massive stroke and died
Catheter removal and compression	Arteriovenous fistula requiring surgical repair
Catheter removal and compression	Left hemothorax requiring blood transfusion
Catheter removal and compression	Pleural effusion, lung collapse, thoracic surgery to repair arterial injury and lung decortication
Catheter removal and compression	Hematoma and uncontrolled bleeding requiring open surgery to repair jugular vein and carotid artery
6 cases of open surgical repair	No complications
2 cases of endovascular repair	No complications

space. While the mediastinum has relatively little potential space, the potential pleural space is up to approximately 3 liters, as the lung is completely compressible. Clearly, a catheter that perforates an artery or a vein and also perforates and communicates with the pleural space rapidly can result in life-threatening hemorrhage. Hemorrhage into the pleural space may increase with removal of the catheter since the catheter may be filling the perforation. This is a key reason that large-bore catheters that have been misplaced should not be removed blindly, without imaging studies to define the anatomic pathway of the catheter and determine a plan for prevention and treatment of hemorrhage that might occur after removal of the catheter.

The risk of causing a hemothorax should be the primary consideration if blood cannot be aspirated after attempted placement of a catheter into the internal jugular or subclavian veins. A catheter from which blood cannot be aspirated after placement should not be removed without first understanding the implications. The catheter may be subcutaneous, extrapleural or intrapleural, and may or may not have traversed blood vessels; but there is no way to know this without performing suitable imaging. An intrapleural catheter that has traversed a vein or artery before entering the pleural space actually may be plugging a pathway for blood to flow into the pleural space when the catheter is removed. Imaging can begin with a simple chest x-ray to locate the tip of the catheter. Injection of contrast into the catheter also may be helpful in determining the location of the catheter. Ultimately, consultation with a vascular surgeon and/or interventional radiologist may be necessary to obtain angiograms to further elucidate the pathway of the catheter and determine the type of vascular injury (if any) and develop a plan for removal of the errant catheter. Examples of cases in which catheters were inserted but blood could not be aspirated are shown in Figures 9 and 10.

CONCLUSIONS

The most common mechanical complication of CVC placement is inadvertent cannulation of an artery. This potentially is a very serious complication. The combined use of ultrasound guidance and pressure measurement is recommended to minimize the incidence of this problem. The recommended treatment for a large-bore catheter placed into an artery in the neck or chest is to leave the catheter in place and seek assistance from vascular surgery and interventional radiology consultants. Direct surgical repair or endovascular repair appears to be much safer than the "pull-and-pressure" approach. Mechanical injuries to veins also can occur. In most cases, injuries to veins probably are due to trapping the guidewire against the wall of the vein and perforating the vein with a stiff dilator or catheter. Fluoroscopy should be helpful for avoiding this problem, but seldom is available in anesthesia, critical care or emergency medicine practice. Assuring that the guidewire can be moved back and forth a few centimeters during insertion of the CVC is an advisable practice that may help to identify a wire that is trapped against the wall of a vein. If blood cannot be aspirated after insertion of a CVC, it should not be removed until suitable imaging is obtained and a plan is devised to control any bleeding that might result at the time of removal.

REFERENCES

1. Hewlett AL, Rupp ME: New developments in the prevention of intravascular catheter associated infections. Infect Dis Clin North Am 26:1-11, 2012
2. Hoff TJ, Soerensen C: No payment for preventable complications: Reviewing the early literature for content, guidance, and impressions. Qual Manag Health Care 20:62-75, 2011
3. Domino KB, Bowdle TA, Posner KL, et al: Injuries and liability related to central vascular catheters: A closed claims analysis. Anesthesiology 100:1411-1418, 2004
4. Agency for Healthcare Research and Quality (AHRQ): National Quality Measures C. Accidental puncture or laceration (provider-level): Rate per 1,000 discharges. Available at: http://www.qualitymeasures.ahrq.gov/content.aspx?id=38525. Accessed March 21, 2013
5. Ezaru CS, Mangione MP, Oravitz TM, et al: Eliminating arterial injury during central venous catheterization using manometry. Anesth Analg 109:130-134, 2009
6. Jobes DR, Schwartz AJ, Greenhow DE, et al: Safer jugular vein cannulation: recognition of arterial puncture and preferential use of the external jugular route. Anesthesiology 59:353-355, 1983
7. Oliver WC, Jr., Nuttall GA, Beynen FM, et al: The incidence of artery puncture with central venous cannulation using a modified technique for detection and prevention of arterial cannulation. J Cardiothorac Vasc Anesth 11:851-855, 1997
8. Hameeteman M, Bode AS, Peppelenbosch AG, et al: Ultrasound-guided central venous catheter placement by surgical trainees: A safe procedure? J Vasc Access 11:288-292, 2010
9. Kron IL, Joob AW, Lake CL, et al: Arch vessel injury during pulmonary artery catheter placement. Ann Thorac Surg 39: 223-224, 1985
10. Golden LR: Incidence and management of large-bore introducer sheath puncture of the carotid artery. J Cardiothorac Vasc Anesth 9: 425-428, 1995
11. Pikwer A, Acosta S, Kolbel T, et al: Management of inadvertent arterial catheterisation associated with central venous access procedures. Eur J Vasc Endovasc Surg 38:707-714, 2009
12. Wicky S, Meuwly JY, Doenz F, et al: Life-threatening vascular complications after central venous catheter placement. Eur Radiol 12: 901-907, 2002
13. Shah KB, Rao TL, Laughlin S, et al: A review of pulmonary artery catheterization in 6,245 patients. Anesthesiology 61:271-275, 1984
14. Najafi A, Moharari RS, Khajavi MR, et al: A giant subclavian pseudoaneurysm following central venous catheterization. J Anesth 23: 628-629, 2009
15. Shah PM, Babu SC, Goyal A, et al: Arterial misplacement of large-caliber cannulas during jugular vein catheterization: Case for surgical management. J Am Coll Surg 198:939-944, 2004
16. Guilbert MC, Elkouri S, Bracco D, et al: Arterial trauma during central venous catheter insertion: Case series, review and proposed algorithm. J Vasc Surg 48:918-925, 2008
17. Troianos CA, Jobes DR, Ellison N: Ultrasound-guided cannulation of the internal jugular vein. A prospective, randomized study. Anesth Analg 72:823-826, 1991
18. Randolph AG, Cook DJ, Gonzales CA, et al: Ultrasound guidance for placement of central venous catheters: a meta-analysis of the literature. Crit Care Med 24:2053-2058, 1996
19. Hind D, Calvert N, McWilliams R, et al: Ultrasonic locating devices for central venous cannulation: meta-analysis. BMJ 327: 361, 2003

20. Mansfield PF, Hohn DC, Fornage BD, et al: Complications and failures of subclavian-vein catheterization. N Engl J Med 331: 1735-1738, 1994

21. Polderman KH, Girbes AJ: Central venous catheter use. Part 1: Mechanical complications. Intensive Care Med 28:1-17, 2002

22. National Institute for Clinical Excellence: Guidance on the use of ultrasound locating devices for placing central venous catheters. Available at http://www.nice.org.uk/nicemedia/live/11474/32461/32461.pdf. Accessed March 21, 2013

23. Rupp SM, Apfelbaum JL, Blitt C, et al: Practice guidelines for central venous access: A report by the American Society of Anesthesiologists Task Force on Central Venous Access. Anesthesiology 116: 539-573, 2012

24. Lamperti M, Bodenham AR, Pittiruti M, et al: International evidence-based recommendations on ultrasound-guided vascular access. Intensive Care Med 38:1105-1117, 2012

25. Troianos CA, Hartman GS, Glas KE, et al: Guidelines for performing ultrasound guided vascular cannulation: recommendations of the American Society of Echocardiography and the Society of Cardiovascular Anesthesiologists. J Am Soc Echocardiogr 24: 1291-1318, 2011

26. Troianos CA, Hartman GS, Glas KE, et al: Special articles: Guidelines for performing ultrasound guided vascular cannulation: recommendations of the American Society of Echocardiography and the Society Of Cardiovascular Anesthesiologists. Anesth Analg 114:46-72, 2012

27. Bailey PL, Glance LG, Eaton MP, et al: A survey of the use of ultrasound during central venous catheterization. Anesth Analg 104: 491-497, 2007

28. Harris N, Hodzovic I, Latto P: A national survey of the use of ultrasound locating devices for placing central venous catheters. Anaesthesia 62:306-307, 2007

29. Pillai L, Zimmerman P, d'Audiffret A: Inadvertent great vessel arterial catheterization during ultrasound-guided central venous line placement: A potentially fatal event. J Vasc Surg 53:74S, 2011

30. Blaivas M: Video analysis of accidental arterial cannulation with dynamic ultrasound guidance for central venous access. J Ultrasound Med 28:1239-1244, 2009

31. Parsons AJ, Alfa J: Carotid dissection: A complication of internal jugular vein cannulation with the use of ultrasound. Anesth Analg 109: 135-136, 2009

32. Chapman GA, Johnson D, Bodenham AR: Visualisation of needle position using ultrasonography. Anaesthesia 61:148-158, 2006

33. Thompson C, Barrows T: Carotid arterial cannulation: Removing the risk with ultrasound? Can J Anaesth 56:471-472, 2009

34. Kulvatunyou N, Heard SO, Bankey PE: A subclavian artery injury, secondary to internal jugular vein cannulation, is a predictable right-sided phenomenon. Anesth Analg 95:564-566, 2002

35. Bowdle A, Kharasch E, Schwid H: Pressure waveform monitoring during central venous catheterization. Anesth Analg 109: 2030-2031, 2009

36. Leone BJ: Con: manometry during internal jugular cannulation: case not proven. Anesth Analg 109:6-7, 2009

37. Togashi K, Nandate K, Hoaglan C, et al: Multicenter valuation of a compact, sterile, single-use pressure transducer for central venous catheter placement. Anesth Analg 116:1018-1023, 2013

38. Stegemann E, Stegemann B, Marx N, et al: Effect of preinterventional ultrasound examination on frequency of procedure-related vascular complications in percutaneous coronary interventions with transfemoral approach. Am J Cardiol 108:1203-1206, 2011

39. Schwartz AJ, Jobes DR, Greenholo DE: Carotid artery puncture with internal jugular cannulation. Anesthesiology 51:S160, 1979

40. Kim JB, Jung HJ, Lee JM, et al: Subclavian artery penetration involving central line access treated with a self-expanding stent. Eur J Cardiothorac Surg 38:801, 2010

41. Melas N, Saratzis A, Saratzis N, et al: Endovascular repair of inadvertent subclavian artery perforation during cannulation for dialysis access: case report and review of the literature. Eur J Emerg Med 16: 323-326, 2009

42. Nicholson T, Ettles D, Robinson G: Managing inadvertent arterial catheterization during central venous access procedures. Cardiovasc Intervent Radiol 27:21-25, 2004

43. Powers CJ, Zomorodi AR, Britz GW, et al: Endovascular management of inadvertent brachiocephalic arterial catheterization. J Neurosurg 114:146-152, 2011

44. Shetty SV, Kwolek CJ, Garasic JM: Percutaneous closure after inadvertent subclavian artery cannulation. Catheter Cardiovasc Interv 69:1050-1052, 2007

45. Wolfe TJ, Smith TP, Alexander MJ, et al: Endovascular treatment of inadvertent cannulation of the vertebro-subclavian arterial junction. Neurocrit Care 6:113-116, 2007

46. Oropello JM, Leibowitz AB, Manasia A, et al: Dilator-associated complications of central vein catheter insertion: possible mechanisms of injury and suggestions for prevention. J Cardiothorac Vasc Anesth 10: 634-637, 1996